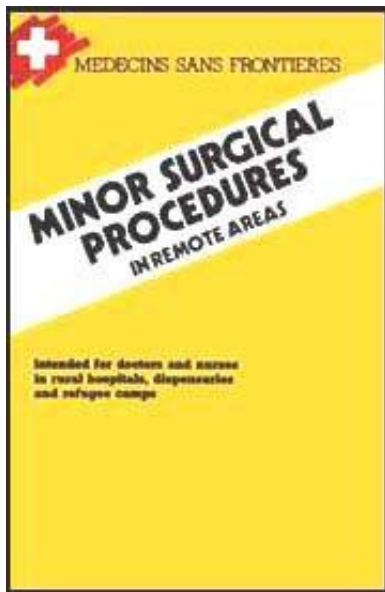















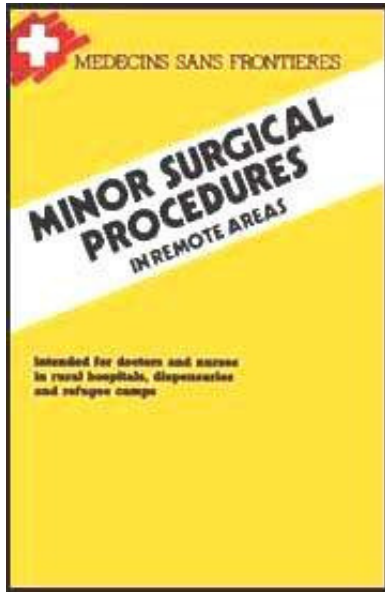


- ➔  **Minor Surgical Procedures in Remote Areas (MSF, 1989, 172 p.)**
-  **(introduction...)**
-  **Notice**
- Chapter 1: Wounds - Burns**
  -  **Dressings**
  -  **Wounds**
  -  **Burns**
- Chapter 2: Infection of soft tissues**
  -  **Abscess**
  -  **Treatment of tropical myositis**
  -  **Infections of the hand and fingers**
- Chapter 3: Catheterisation and drainage**
  -  **Catheterisation of large veins**
  -  **Lumbar puncture**
  -  **Pleural puncture**
  -  **Thoracic drainage**
  -  **Pericardial puncture**
  -  **Drainage of ascites and intra-peritoneal perfusion**
  -  **Puncture and drainage of the knee**
- Chapter 4: ent procedures**












-  **Epistaxis**
-  **Ear drainage**
-  **Dental extraction**
- Chapter 5: uro-genital procedures**
  -  **Urinary catheterisation**
  -  **Reduction of a paraphymosis**
  -  **Episiotomy**
  -  **Suturing episiotomies or perineal tears**
  -  **Intra-uterine procedures**
  -  **Treatment of a bartholin abscess**
- Chapter 6: treatment of trauma**
  -  **Fractures and dislocations: the basics**
  -  **Shoulder and arm trauma**
  -  **Trauma of the lower limb**
  -  **Period of immobilization for major fractures**
- Appendix**
  -  **List of essential supplies (absolutely necessary)**
  -  **Disinfection and Sterilization of medical equipment and supplies**
-  **Bibliography**

[Home](#) > [ar](#).[cn](#).[de](#).[en](#).[es](#).[fr](#).[id](#).[it](#).[ph](#).[po](#).[ru](#).[sw](#)





## **Minor Surgical Procedures in Remote Areas (MSF, 1989, 172 p.)**

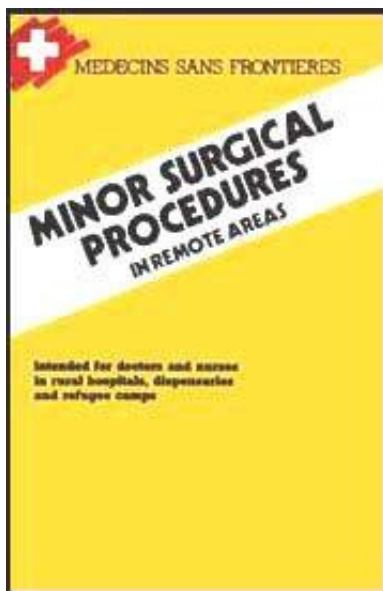
-   **(introduction...)**
-  **Notice**
-  **Chapter 1: Wounds - Burns**
-  **Chapter 2: Infection of soft tissues**
-  **Chapter 3: Catheterisation and drainage**
-  **Chapter 4: ent procedures**
-  **Chapter 5: uro-genital procedures**
-  **Chapter 6: treatment of trauma**
-  **Appendix**
-  **Bibliography**

**intended for doctors and nurses in rural hospitals, dispensaries and refugee camps**

**NOTE FROM THE CD-ROM EDITORS: THIS MANUAL SHOULD BE USED BY MEDICALLY TRAINED PERSONS ONLY. THE GREATEST CARE HAS BEEN GIVEN TO ACCURATE REPORT BUT IT CAN NOT BE TOTALLY EXCLUDED SOMETIMES A TYPESETTING OR SCANNING ERROR HAS OCCURRED (ON AVERAGE 1 OUT OF 2000 TO 3000 CHARACTERS IN TEXT AND 1 OUT OF 200 to 300 DIGITS IN TABLES).**

**Mdecins sans frontires - 1989**





## **Minor Surgical Procedures in Remote Areas (MSF, 1989, 172 p.)**

 ***(introduction...)***

 **Notice**

 **Chapter 1: Wounds - Burns**

 **Chapter 2: Infection of soft tissues**

 **Chapter 3: Catheterisation and drainage**

 **Chapter 4: ent procedures**

 **Chapter 5: uro-genital procedures**

 **Chapter 6: treatment of trauma**

 **Appendix**

  **Bibliography**

## **Bibliography**

### **1. ABOULKER P.**

**Techniques en urologie Flammarion, edition 1984**

### **2. AGREGES DU PHARO**

**Techniques elementaires pour medecins isoles: techniques chirurgicales D.G.D.L. edition 1983**

**3. BORGHI R., BUTEL J.**

**Manuel du traitement orthopedique des fractures des membres et des ceintures  
Masson, edition 1981**

**4. DETRIE P.**

**Chirurgie d'urgence Masson, edition 1985**

**5. DETRIE P.**

**Petite chirurgie Masson, edition 1980**

**6. EDITIONS TECHNIQUES**

**Encyclopedie mdicaux - chirurgicale: volumes de techniques chirurgicales Editions  
Techniques, 18 rue Segulier, Paris 75006**

**7. GINESTET G., FREZIERES H., DUPUIS A., PONS J.**

**Chirurgie plastique et reconstructive de la face Flamarion, edition 1967**

**8. ISELIN M. et F.**

**Atlas de chirurgie de la main Flamarion, edition 1971**

**9. KLIPPEL A.P., ANDERSON C.B.**

**Manuel de techniques chirurgicales applicables en urgence et en consultation**

**externe de chirurgie MEDSI collection Spirale, edition 1985**

**10. LAHBANI SAID**

**Traitement non sanglant des fractures, tome 1 Maloine/Sochepress, edition 1983**

**11. LEGER L.**

**Semiologie chirurgicale Masson, edition 1974**

**12. MERGER R., LEVY J., MELCHIOR J.**

**Precis d'obstetrique Masson, edition 1985**

**13. ORSONI P.**

**Manuel de l'aide en chirurgie Masson, edition 1976**

**14. PATTEL A.**

**Traumatologie Masson, edition 1983**

**Imprime en France par Pollina, 85400 Lucon - n° 11969 Depot legal n° 8285 -  
decembre 1989**

**FRANCE**

**Medecins sans Frontieres 8 rue Saint-Sabin 75011 PARIS Tel.: 40.21.29.29**

**BELGIUM**

**Mdecins sans Frontieres 24/25 rue Deschamphelaar 1080 Bruxelles Tel.: (32)  
2.425.03.00**

**NEDERLAND**

**Artsen Zonder Grenzen Postadres - Postbus 10014 1001 EA Amsterdam Tel.: (31)  
20.25.12.72**

**SWITZERLAND**

**Medecins sans Frontieres 10 Chemin Malombre 1206 Geneve Tel.: (41) 22.47.15.00**

**SPAIN**

**Medicos sin Fronteras Luis Sagnier 64 - 66 entlo. 1º 08032 Barcelona Tel.: (34)  
3.412.52.52**

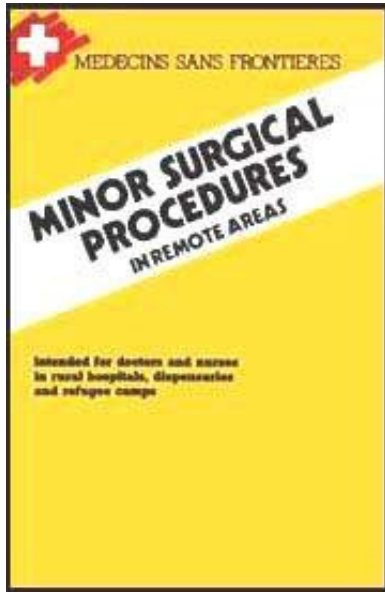
**LUXEMBOURG**











**Mdecins sans Frontieres 110 Avenue Gaston Diderich L1420 Luxembourg Tel.: (352)  
45.88.12**



[Home](#) > [ar](#).[cn](#).[de](#).[en](#).[es](#).[fr](#).[id](#).[it](#).[ph](#).[po](#).[ru](#).[sw](#)

 **Minor Surgical Procedures in Remote Areas (MSF, 1989, 172**



- p.)
-  **(introduction...)**
-  **Notice**
-  **Chapter 1: Wounds - Burns**
-  **Chapter 2: Infection of soft tissues**
-  **Chapter 3: Catheterisation and drainage**
-  **Chapter 4: ent procedures**
-  **Chapter 5: uro-genital procedures**
-  **Chapter 6: treatment of trauma**
-  **Appendix**
-  **Bibliography**

## Notice

**This guide contains the most frequent and useful minor surgical procedures practices by doctors and nurses in remote areas with poor sanitation and no surgical or radiography equipment.**

## EDITOR:

**RIGAL Jean (P)**

## CONTRIBUTORS (IN ALPHABETICAL ORDER):

**COMBREAU Jacqueline (M)**

**DESENCLOS Jean-Claude (P)**



**FAUCHER Bruno (P)**  
**GOSSOT Dominique (S)**  
**JORLAND Dominique (DS)**  
**LANSSADE Regis (N)**  
**LEGRAND Luc (N)**  
**MORINIERE Bernard (P)**  
**PORTER John (P)**  
**PRIGNON Jehan (S)**  
**RENCHON Brigitte (Ph)**  
**ROUAM L.W. (S)**  
**SEGALA Claire (P)**

**(P) Physician, (S) Surgeon, (DS) Dental-Surgeon, (N) Nurse, (M) Midwife, (Ph) Pharmacist**

**This work could not have been accomplished without the skill and assistance of Miss Laissu E. who typed and corrected the manuscript.**

**© Hatier Paris - Decembre 1989**

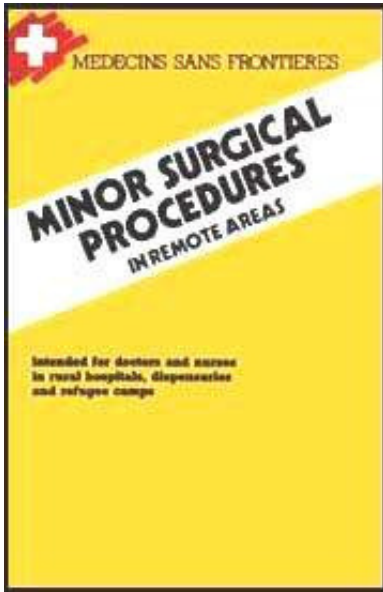
**© Medecins sans Frontieres - Decembre 1989**

**Tous droits de reproduction, de traduction et d'adaptation reserves pour tous pays.**

**ISBN 2-218-02163-3**



**[Home](#) > [ar](#).[cn](#).[de](#).[en](#).[es](#).[fr](#).[id](#).[it](#).[ph](#).[po](#).[ru](#).[sw](#)**



## **Minor Surgical Procedures in Remote Areas (MSF, 1989, 172**

**p.)**



### **Chapter 1: Wounds - Burns**



**Dressings**



**Wounds**



**Burns**

## **Minor Surgical Procedures in Remote Areas (MSF, 1989, 172 p.)**

### **Chapter 1: Wounds - Burns**

#### **Dressings**

**Dressing is a set of procedures for treating a wound. A wound is an interruption in the continuity of the skin secondary to trauma or surgery.**

#### **Objectives**

- **Protection:**

- **To prevent contamination from the external environment**
- **To protect against possible trauma**

- **Cicatrisation:**

- **To favor tissue regeneration**

- **Absorption:**

- **To absorb serous discharge**

- **Disinfection:**

- **To destroy pathogenic organisms**

- **Compression:**

- **To stop hemorrhage**

**Warning: A dressing occludes a wound and in certain conditions (humidity, heat) can encourage multiplication of pathogenic organisms.**

## **Equipment**

- **1 box of sterile instruments - 1 set of dissection forceps - 1 set of Kocher forceps**
- **1 pair of scissors**
- **1 dressing tray (clean)**
- **1 drum of sterile gauze pads**
- **1 kidney dish**
- **Cotton wool (for equipment disinfection only, never use cotton wool directly on a wound)**

- **Adhesive tape**

- **Flasks containing antiseptics: chloramine and/or cetrимide-chlorhexidine, and polyvidone iodine (dilution: see table).**

**N. B. : Never use polyvidone iodine with soaps containing mercurial derivatives. Solution preparation should be rigorous. Solutions should be renewed every week (every 3 days for chloramine).**

### **General rules of asepsis**

- **A room should be kept for dressings. It should be carefully cleaned everyday and dressing tables should be disinfected between each patient.**
- **Use a sterile box of instruments for each dressing, or at least for each patient.**
- **Always start from the clean area and move to the dirty one.**
- **Wash hands carefully after each dressing, and after removing bandages or adhesive tape.**

### **Technique**

#### **Equipment and instrument preparation**

- **Cleaning of the dressing tray with cetrимide-chlorhexidine (dilution: see table).**
- **Removal of the previous dressing**
- **Removal of bandages and adhesive tape (not the gauze pads)**
- **Hand washing (clean water + soap)**

- **Removal of gauze pads, using Kocher forceps**

- **If the dressing adheres, soak it with sodium chloride solution or an antiseptic.**
- **Act gently not to remove the granulating epidermis.**

## **Wound examination**

- **Sutured wound and/or aseptic wound:**

- **Check the stage of cicatrization if wound is weeping, has a hematoma, or is infected.**

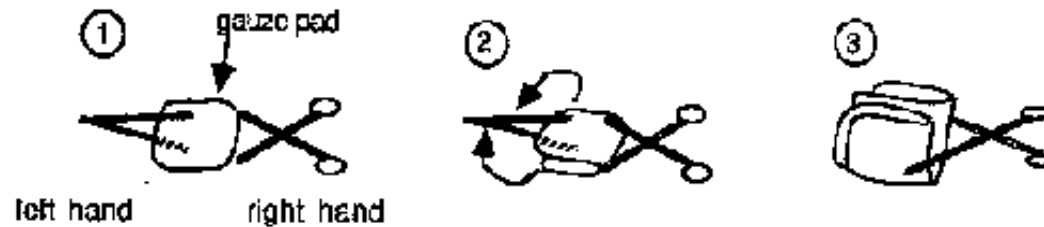- **Septic wound:**

- **Check the nature of secretions and if there are new fleshy pimples.**
- **A bluish pus indicates the presence of pyocianic (quickly spreading, very resistant bacillus spreading very quickly).**
- **Look for any signs of lymphangitis.**
- **Use new forceps after removal of the dirty dressing and the first cleaning of the wound.**

## **Cleaning of the wound**

- **Use the sterile dissection forceps to remove sterile gauze pads from the container, and place them on the tray.**

- **To make a sterile sponge fold the pads twice using the Kocher and dissection forceps (as illustrated).**

**FIGURE**

- **Pour an antiseptic solution on the pad (infected wound, bures, abcess, ulcers: cetrimide-chlorhexidine; non infected surgical wound: polyvidone iodine (dilution: see table, page 7)).**
- **Clean the periphery of the wound either with a circuler movement, or from top to bottom. Change gauze pads as often as necessary.**
- **Clean the wound from top to bottom with a new tampon.**
- **Dry the periphery of the wound and then the wound itself with different gauze pads.**

### **Dressing a wound**

- **Apply one or several gauze pads to the wound**
- **Apply strips of adhesive tape: - Perpendicularly to the axis of the limb or the body - Leave the central part free to avoid maceration**

**N.B.: When sterile disposable material is limited, sterile pads should be reserved for aseptic and surgical wounds.**

## **Frequency of dressings**

- **Surgical wounds, or non infected sutures:** - First day dressing should be well protected - Further dressings, every 48 to 72 h (check the process of recovery).
- **Infected wounds:** - Dress every 24 h.
- **Deep or large burns:**
  - Dress on the first day, then leave until the 7th day (unless obvious infection)
- **Phagedenic ulcers:**
  - Dress every 24 h, with hospitalization if possible.

## **Associated antibiotic treatment**

**As a rule, systemic antibiotic treatment should not be prescribed routinely.**

- **Deep and soiled wounds, to prevent gas gangrene:** procain-penicillin (IM) : 4 or 5 IU per day x 5 days at least.
- **Abcess:** antibiotic treatment is useless before incision.
- **Burns:** only if they are infected.
- **During conflicts or other disaster relief conditions, where access to health care and patient's follow-up are hazardous, the systematic use of PPF (or procain-penicillin) should be considered.**

## Wastes

**All soiled disposable materials (gauze, coton, dressings, etc.) should be collected and burned daily.**

INDICATIONS	PRODUCT TO BE USED	DILUTION	SHELF LIFE	COMMENTS
<ul style="list-style-type: none"> <li>FRESH WOUNDS</li> <li>HAND WASHING</li> <li>SKIN CLEANING (e.g. before injections)</li> <li>PERINEAL CLEANING BEFORE DELIVERY</li> <li>INFECTED WOUNDS (pus smell...)</li> <li>ABSCESS</li> <li>FURUNCLES</li> <li>INFECTED ULCERS... (anything purulent)</li> </ul>	CHLORHEXIDINE (1.5%) CETRIMIDE (1.5%) • HAC® or Sazon® or CHLORHEXIDINE (5%) or ORDINARY SOAP	20 ml per litre  10 ml per litre	To renew once a week	Never to be used for wounds to the skull or ear. Never to be used with soap.
<ul style="list-style-type: none"> <li>MYCOSIS (e.g.: thrush)</li> <li>RUNNING DERMATOSIS (eczema, impetigo)</li> <li>SUPERFICIAL BURNS</li> <li>SMALL AND SUPERFICIAL WOUNDS</li> </ul>	TOSYLO ILORAMIDE = CHLORAMINE™	2 g per litre (equivalent to DAKIN's solution)	To renew twice a week	Place in a brown coloured glass or opaque flask (non metallic). In case of prolonged use, protect the healthy skin around the wound with vasellin.
<ul style="list-style-type: none"> <li>FIXING OF IV CATHETER, LUMBAL PUNCTION</li> <li>UMBILICAL CORD</li> <li>OPERATIVE FIELD</li> <li>SURGICAL WOUNDS BEFORE SUTURE</li> </ul>	GENTIAN VIOLET	Saturated solution (5 g/l 1 teaspoon/litre. Shake several times, let decant. Filter or pour carefully in another flask in order to eliminate any deposit.	To renew once a week	Not to be used on the face of light coloured persons, as it could provoke persistent pigmentation.
<ul style="list-style-type: none"> <li>POST DRESSING (change of dressing)</li> <li>SITE OF INJECTION</li> </ul>	POLYDOME IODINE (10%) PVI = Ectadone®	Pure (= 10% PVI)	To renew once a week	Never to be used with a mercurial derivative (Merfenol, Mercurochrome®), disinfectant liquid soap.
<ul style="list-style-type: none"> <li>FLOORS, WASH-BASINS</li> <li>TABLES, KITCHEN DISHES, DRAWSHEETS...</li> </ul>	LYSOL or CHLORINE SOLUTION	Lysol: 20 to 50 ml/l according to cleanliness Bleach 12° (5% chlorine): 50 ml/l Ca Hypochlorite (70% chlorine): 3 g/l (2 table spoons per 10 l of water) Chloramine: 5 g/l	Prepare immediately before use	Precautionary measures in using chlorine solution: Do not use metallic buckets. Do not mix with a detergent. For smooth surfaces, begin with preliminary cleaning.

Table 1 - Antiseptic and disinfectant

**TABLE 1**



# Wounds

## General principles

**This chapter concerns only wounds that can be treated at a dispensary level. For major trauma, refer to a surgical manual.**

- **Immediate ("primary") closure of wounds is desirable but not always practicable and in some circumstances it may be dangerous (risk of infection).**
- **Classically, it is said that a wound of greater than 6 hours should not be sutured. In isolated rural practice, however, patients often present late because of distances and this limit may be extended up to 24 hours, provided the patient can be observed during the following days for signs of infection.**
- **An infected wound should never be sutured.**
- **War wounds, animal and human bites should not be sutured.**
- **Any break in the skin overlying a fracture is an "open fracture".**
- **A wound that communicates with a joint is an open joint wound.**
- **Always give antitetanus prophylaxis if available.**

**The following are steps in the treatment of a wound: preparation, exploration, debridement, closure, drainage, and finally removal of sutures.**

## Preparation

## **Wound toiles**

- **Shave if necessary, then clean the wound and its periphery with iodine povidone Betadine**

### **Material**

**(Figures 1a a 1d et 2a a 2c)**

- **Sterile gloves and fenestrated drapes.**
- **Lidocaine, needle and syringe.**
- **Suture material.**
- **Suture set (sterilized box of instruments): needle holder, needles, scalpel blade and handle, one or two artery forceps, fine curved scissors with rounded ends, plain scissors for cutting sutures, retractors.**

### **Local anesthesia**

- **Only necessary for large or deep wounds requiring more then 2 stitches.**
- **Lidocaine 1% without adrenaline.**
- **Infiltrate subcutaneously via the wound edges.**

### **Exploration**

**Once anesthetized, the wound can be explored and thoroughly cleaned of any**

**debris. Have a gloved assistant using retractors if necessary. Be careful to exclude the following:**

- **Foreign body.**
- **Underlying fracture.**
- **Involvement of nerves, major blood vessels, tendons or joints.**
- **For scalp wounds: underlying fracture (if serious may contain brain tissue).**

## **Closure**

- **Use interrupted sutures (not continuous).**
- **Non-resorbable sutures such as silk for skin, resorbable thread (chromic catgut, Vicryl.) for subcutaneous tissues.**
- **Some suture material is already mounted on a needle by the manufacturer ("atraumatic needles").**
- **A curved needle is easier to manipulate.**
- **For skin use a "cutting" needle (triangular in cross-section); for subcutaneous tissues use a "round" needle (circular in cross-section).**

**Table 2 : Suture materials recommended for different wounds**

<i>Skin of face</i>	Nylon or silk	dec. 2,5 (= 3/0)
<i>Skin of scalp</i>	Nylon or silk	dec. 3 (= 2/0)
<i>Skin of limbs or trunk</i>	Nylon or silk	dec. 2,5 or 3 (= 3/0 or 2/0)
<i>Subcutaneous tissue</i>	Catgut (plain or chromic)	dec. 3 (= 2/0)
<i>Aponeurosis</i>	Chromic catgut	dec. 3 (= 2/0)
<i>Muscle</i>	Chromic or other slowly resorbable (e.g. Vicryl)	dec. 3 (= 2/0)

**N.B. :** - From 0 to 3/0 the suture becomes increasingly fine in caliber.  
 - Resorbable synthetic : resorbs slowly (over 3 weeks), e.g. vicryl...

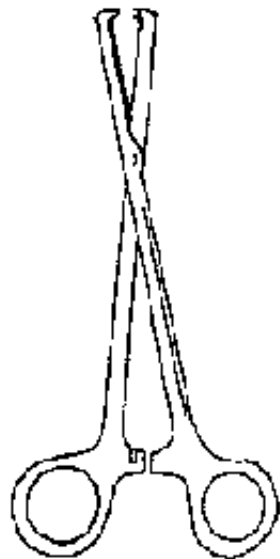## TABLE 2

### Drainage

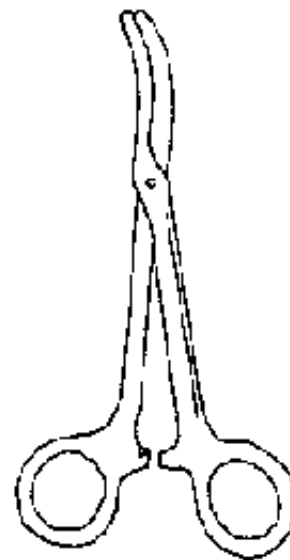
- Use a strip of corrugated rubber drain.
- Never use a drain for wounds of the face.
- Always insert a drain in wounds of the scalp and whenever a hematoma can be expected to form.

### Removal of sutures


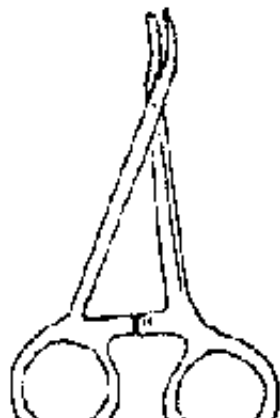
- **Face: day 5.**
- **Other wounds: day 7 or 8.**



**Figure 1a**  
Kocher forceps  
toothed



**Figure 1b**  
Kelly clamp  
curved, untoothed

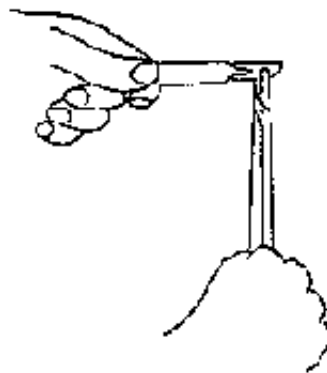


**Figure 1c**  
Mosquito forceps curved and  
untoothed (also called artery  
clamp or hemostat)

**Figure 1d**  
Retractor (Farabeuf type)

**Figures 1 : DIFFERENT INSTRUMENTS**

## FIGURE



**Figure 2a :** Always mount a scalpel blade using a needle holder. Change blades for each different operation (even on the same patient).



**Figure 2b :** Dissecting (toothed) forceps should not be held in the palm but between the thumb and index finger. They should be used on skin only.



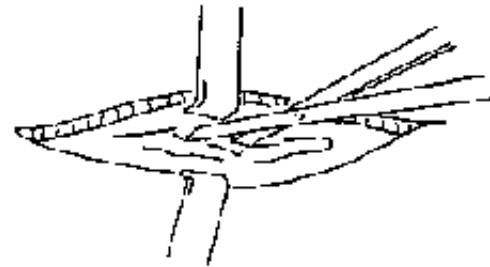
**Figure 2c :** Insert the thumb and the ring finger into the handle of a needle holder (or scissors), and stabilize the instrument using the index finger.

**Figures 2 : HOW TO HOLD INSTRUMENTS**

## **FIGURE**



**Figure 3a :** debridement of a contused, messy wound : straightening of wound edges with a scalpel. Be very careful on the face.



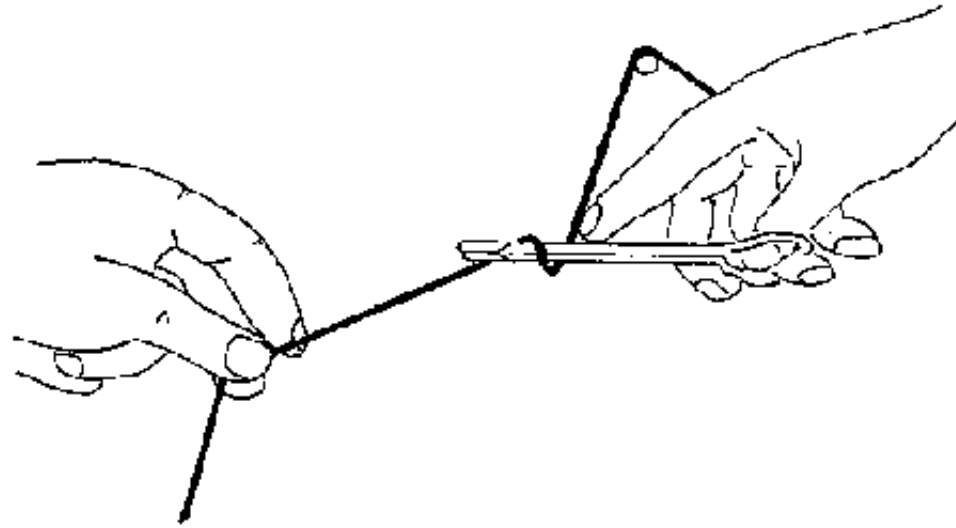
**Figure 3b :** excision of torn edges of aponeurosis to avoid necrosis.



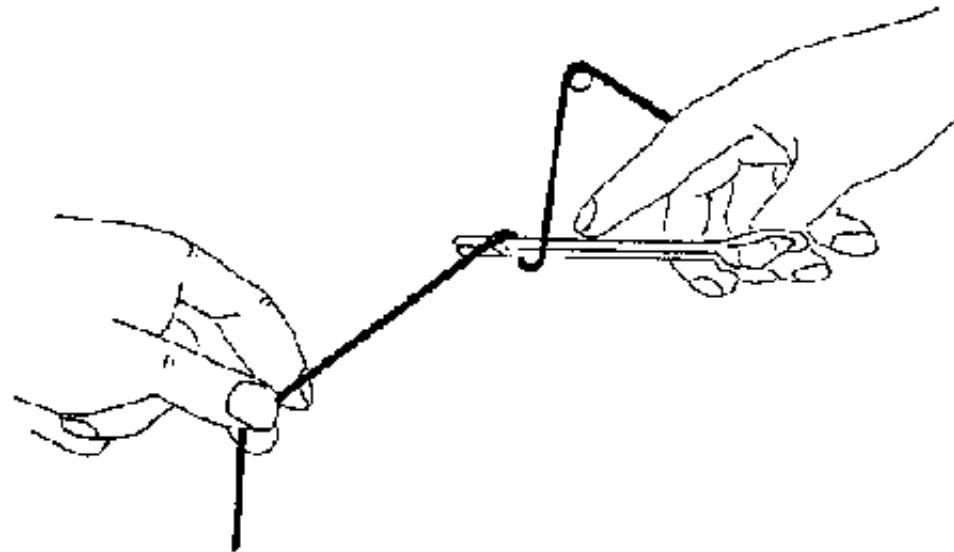
**Figure 3c :** excision of torn or contused muscle

**Figures 3 : DEBRIDEMENT** (this should be sparing, limited to excision of severely contused or lacerated tissue that is evidently destined for necrosis.)



**FIGURE**

**Figure 4a :** loop the suture material around the needle-holder in one direction (e.g. "over towards me") and remember this direction. Take the loose end with the needle holder and pull it through to make the first knot.



**Figure 4b** : the second loop should be in the opposite direction ("under towards me"). Repeat a third knot, changing direction, once again.

**Figures 4 PRACTICE WITH KNOTS**

**FIGURE**



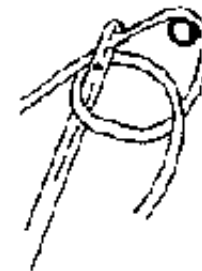**Figure 4c** : the first knot should be flat.



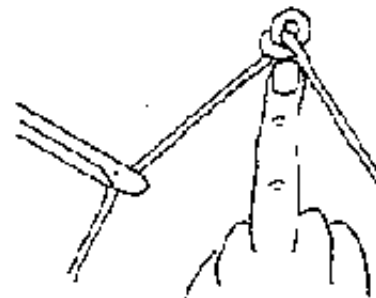
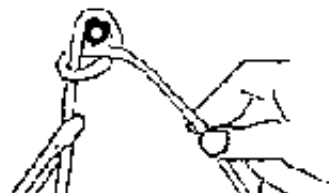**Figure 4d** : second knot : opposite direction.



**Figure 4e**  
Catching the loose end with the needle-holder.



**Figure 4f**





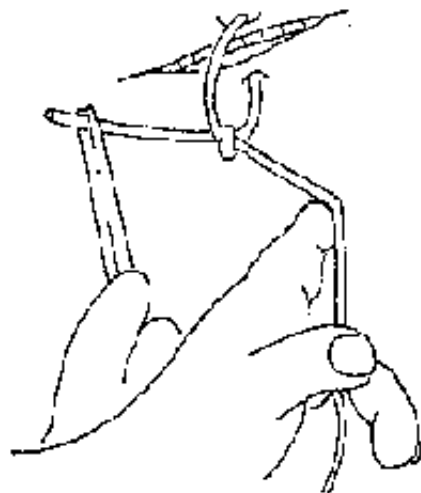
**Figure 4g**

**Figure 4h**

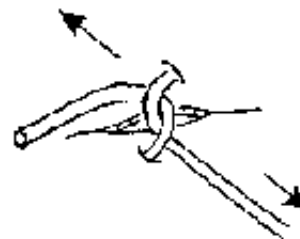
Slip the knot up towards the nail using the hand that holds the free end, holding the other length of suture with the needle-holder.

**Figures 4 : PRACTICE WITH KNOTS (continued)**

**FIGURE**



**Figure 5a : first knot flat.**



**Figure 5b : lighten without causing ischemia (pallor).**

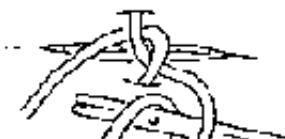



Figure 5c : loose end pulled through.

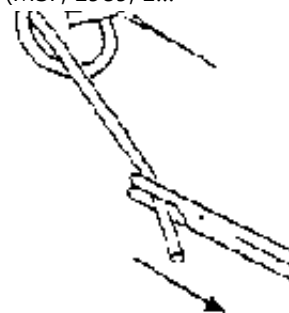


Figure 5d : second knot in opposite direction.

Figures 5 : TYING KNOTS ON SKIN

**FIGURE**

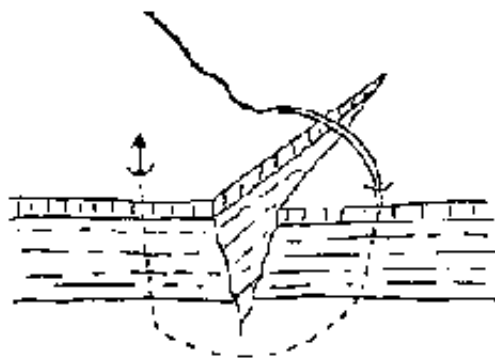


Figure 6a  
The "bite" taken must be sufficiently deep.

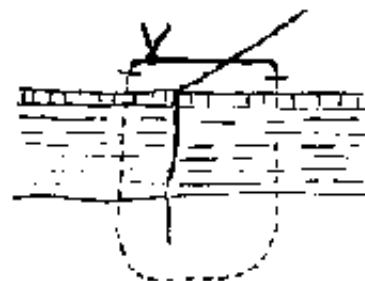
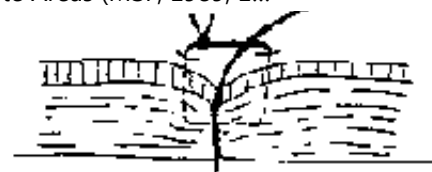


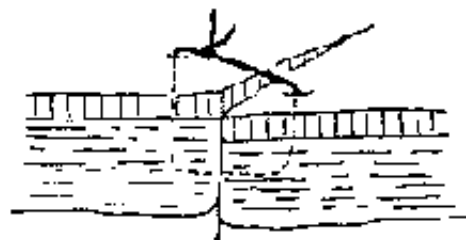
Figure 6b



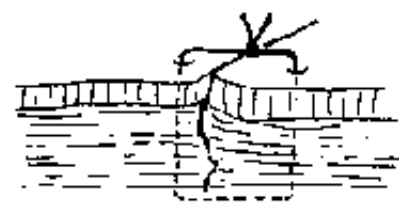
**Figure 6c**  
Incorrect : bite too shallow, so the edges invaginate.



**Figure 6d**



**Figure 6e** : incorrect : poor  
opposition of the edges.



**Figure 6f** : incorrect :  
the knot should be beside  
the wound, not over it

**Figures 6 : PARTICULAR PROBLEMS**

**FIGURE**

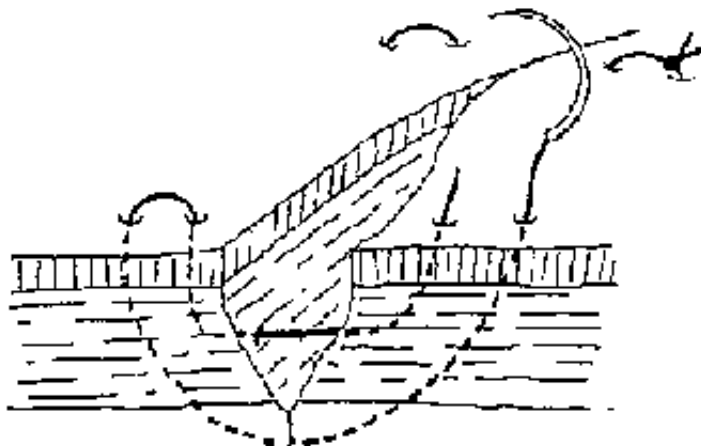


Figure 7

VERTICAL MATTRESS SUTURE (ALSO CALLED BLAIR-DONATI TECHNIQUE) : allows good apposition of the wound edges.

**FIGURE**

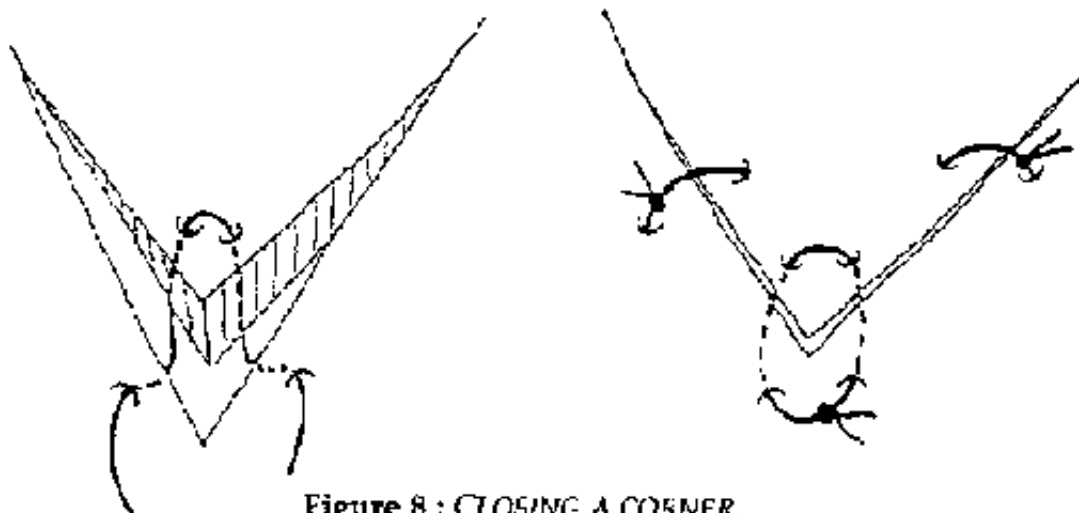
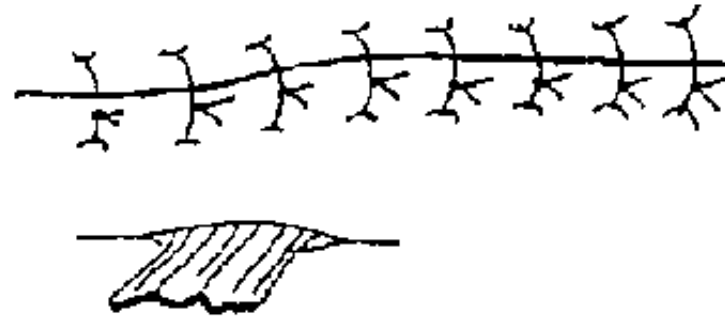


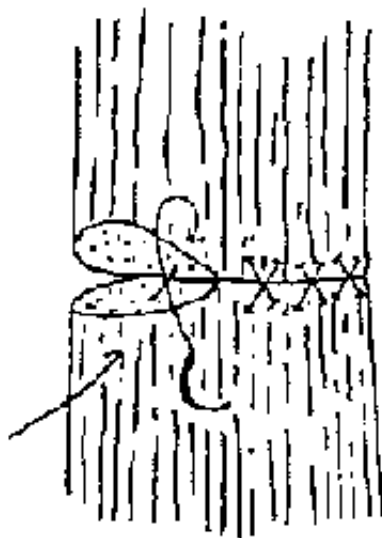
Figure 8 : CLOSING A CORNER.

**FIGURE**



**Figure 9 : REPAIR OF MUSCLE**  
using interrupted sutures  
through the full thickness.  
Use chromic (or Vicryl etc)  
crossed in an X.

**FIGURE**




**Figure 10 : CLOSE SKIN USING INTERRUPTED SILK OR NYLON.**

In case of deep wound, a drain is usually advisable (emerging via a counterincision) to avoid hematoma.

## **FIGURE**





**Figure 11a**

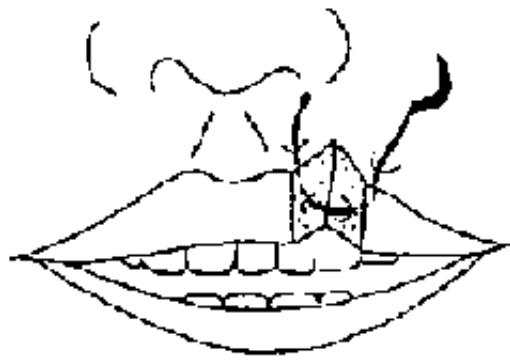

**Figure 11b**

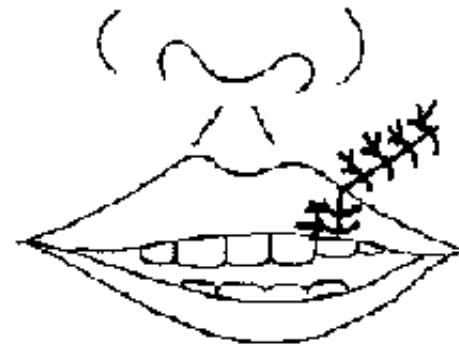Exposed cartilage : resect the bare cartilage and cover with sutured skin. Systemic antibiotics (**Ampicillin** : 2 g/d for adult for at least 8 days)

**Figures 11 : WOUND OF THE EAR**

**FIGURE**



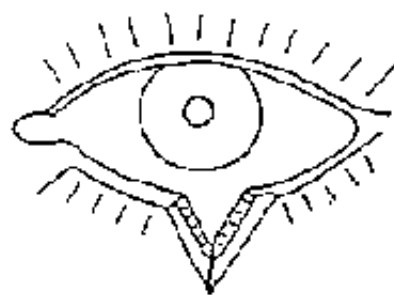
**Figure 12a**  
Start at a point on the mucocutaneous junction



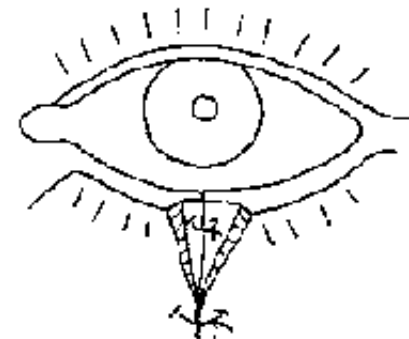
**Figure 12b**  
For all facial wounds, use deep absorbable sutures. On the skin, make small sutures which are equally spaced (1 cm is best).

**Figures 12 : WOUND OF THE LIPS**

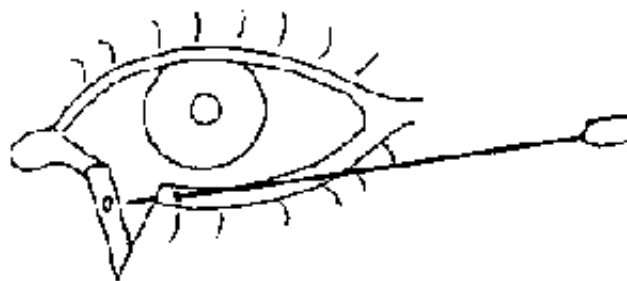
**FIGURE**



**Figure 13a**  
Before suturing the skin, consider the alignment of the mucous membrane



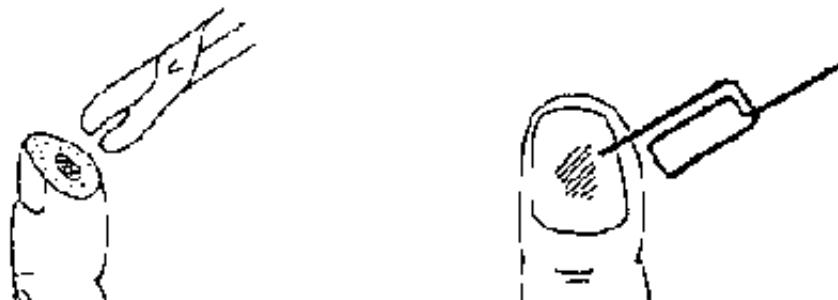**Figure 13b**



**Figure 13c**  
A wound in the internal corner of the eye almost always damages the lacrimal duct : try to catheterize the duct with a small diameter catheter before repairing the eyelid. Leave the catheter for 8 days.

**Figures 13 : WOUND OF THE EYELID**

## FIGURE



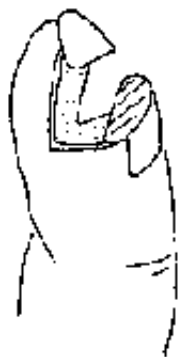

**Figure 14a**

Wound of the tip of the finger :  
Excise a minimal amount of exposed bone. Do not graft, encourage healing with regular dressings. Suturing risks tissue ischemia.

**Figure 14b**

Evacuation of a subungual hematoma using "a hot paper clip" :  
make a hole in the nail with a white hot paper clip, then evacuate the hematoma.



**Figure 14c**

Debridement of the finger tip  
The unguis phalanx is bare. It must be covered by suturing the lateral edges and preserving the nail.



**Figure 14d**

**Figures 14 : WOUNDS OF THE FINGERS**

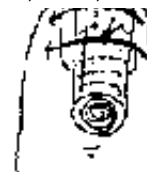**FIGURE**



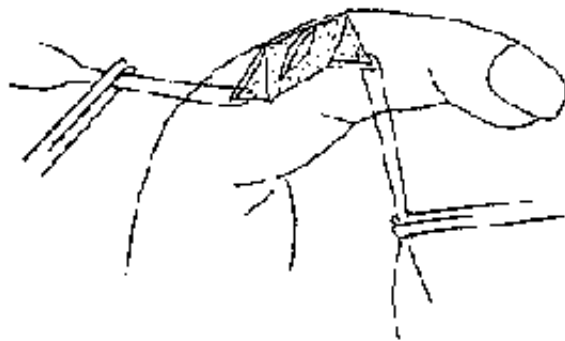

**Figure 14e**

Damage to the nail : keep the nail by fixing it with two sutures at the edge of the finger, and cover the nail with a rolled dressing before loosely tying the sutures.

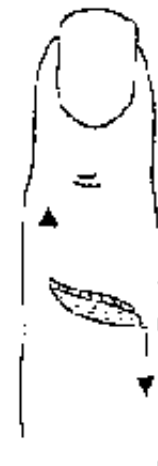

**Figure 14f**



**Figure 14g**

Dorsal wound of the finger : at the level of the interphalangeal joint, this wound almost always involves the extensor tendon.



**Figure 14h**

Do not hesitate to enlarge the wound longitudinally to draw a "Z".



**Figure 14i**

Suturing a tendon with resorbable material : first take a large "bite" of the tendon, then suture the points at the circumference and finally tighten the suture. Immobilize the finger in a functional position for 15 days.

## **FIGURE**

### **Burns**

**Thermal trauma to the skin, mucosa and deeper tissues. Burns are classified according to depth and extent.**

**Any burn that affects greater than 10 % of the body surface area is considered extensive and is thus serious because of fluid loss, catabolism, anemia and the risk of secondary infection. Burns are very common in rural societies, particularly among children who fall onto or roll into cooking fires.**

### **Clinical features**

**The extent of a burn is expressed as a percentage of total body surface area involved, easily estimated by the "rule of nines" (Table 3). The degree is a function of the depth to which tissue damage penetrates (Table 4).**

**A patient with extensive burns is likely to be in shock and requires appropriate resuscitation. Among children, the younger the patient the graver the danger presented by a burn of given extent and degree.**

**Table 3 : "Rule of nines" for calculating percentage of body surface burned**

Body area	Adult (%)	Child (%)
Entire head	9	18
Upper limb	9	9
Anterior or posterior surface of trunk	18	18
Lower limb	18	14
Perineum	1	1

**TABLE 3****Table 4 : Depth of burns**

1st degree	Skin red and tender
2nd degree superficial	Skin red with blistering, tender to touch
2nd degree deep	Skin white, dry and soft Diminished sensibility to touch or pin-prick
3rd degree	Diminished sensibility to touch or pin-prick

**TABLE 4**

## Treatment

### First aid

- **Immerse in cold water; this provides good analgesia and also arrests on-going trauma due to the heat retained in the tissues.**

- **Apply gentian violet.**

- **Do not cover.**

## **Resuscitation**

- **Calculate the fluid requirements for the first 24 hours: weight x % of surface burn x 2 = quantity of fluid required in mls. e.g.: 60 kg (wt) x 20 % (extent of burn)**

**$60 \times 20 \times 2 = 2,400 \text{ml}$**

- **75 % of fluid should be given or Ringers Lactate, the remainder as volume expanders or blood transfusion.**

- **During the first 24 hours, half the fluid requirements should be given in the first 8 hours.**

## **First dressing of the burn**

- **Analgesia pentazocine (IM): 30 mg) and sedation if necessary (diazepam (IM): 10 mg).**

- **Tetanus prophylaxie if available.**

- **Strict aseptic technique: drapes, gloves and instruments all sterile (Figure 15).**



- **Clean the burn with normal saline or chlorhexidine-cetrimide solution (see table, page 7).**
- **Use a scalpel to debride blisters and non-viable tissue.**
- **Apply sterile vaseline gauze, then on top of that two layers of unfolded sterile gauze swabs. Do not use either antibiotic ointment or gauze impregnated with antibiotics or corticosteroids.**
- **Apply a bandage, not tightly. Do not wrap limbs, especially at the flexures as this will encourage contractures. Bandage each finger separately, never together.**
- **Immobilize limbs in the position of function.**
- **Alternatively: "open method": after wound cleaning leave the burn uncovered with the patient protected by a mosquito net.**

### **Subsequent dressings**

- **Unless infection ensues, the first dressing should be left undisturbed for 5 to 7 days.**
- **Analgesia aseptic technique as for the first dressing.**
- **Remove any black eschars (which may hide purulent areas) and use scalpel to excise any necrotic tissue: skin, aponeurosis, muscle or tendon.**
- **Systemic antibiotics if obvious infection (not antibiotic ointment): PPF (IM):**

**Adult : 4 MIU/day x 5 days at least**

**Child : 100,000 IU/kg/day x 5 days at least**

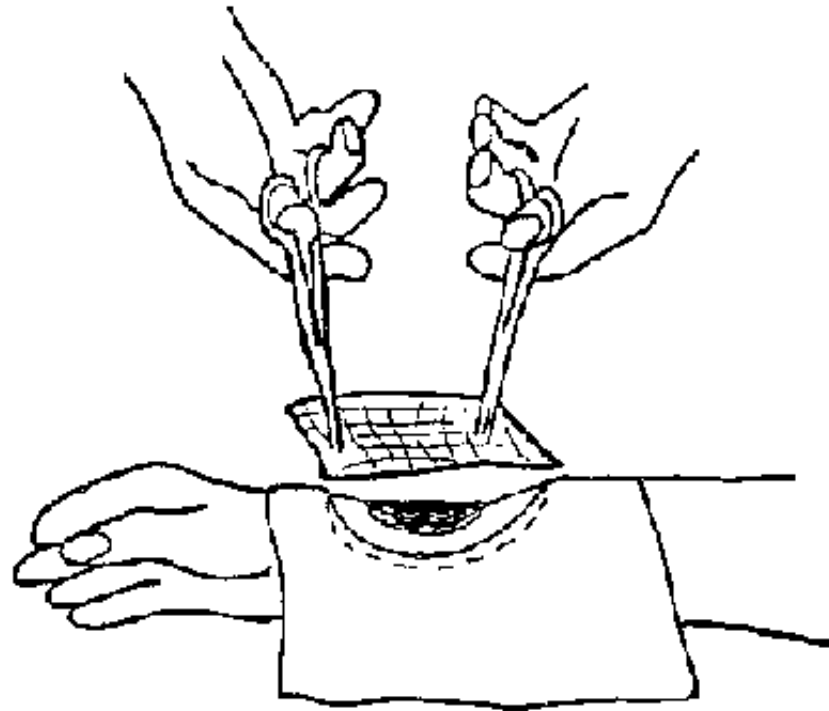
- **Same dressing as the first time. Again, this should not be removed for 5 to 7 days. Healing is signaled by granulation tissue: pink, mat and clean.**

## **Patch grafting**

**(Figure 16)**

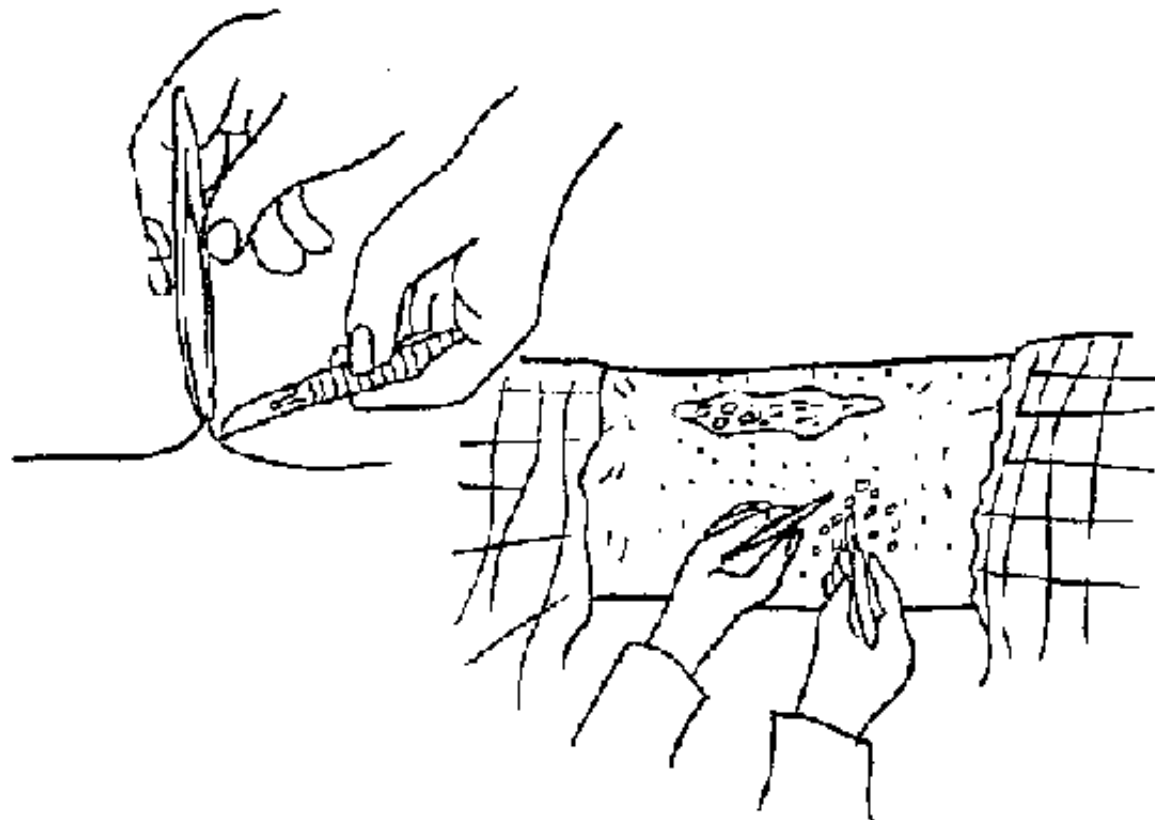
- **Skin grafting is necessary when the wound is slow to heal: often the case with deep second degree and third degree burns. Patch grafting is a simple technique and can also be used for treating tropical ulcers once the base is clean and granulating.**
- **Aseptic technique. Shave the donor area (usually anterior thigh or forearm) and prep with povidone-iodine (see table, page 7). Infiltrate with lidocaine 1%.**
- **Lift up a patch of skin with fine toothed forceps and excise it with a scalpel. It should be full-thickness i.e. epidermis plus dermis. Take other patches from different parts of the donor site, leaving areas of intact skin between each excision.**
- **Spread each patch out on a sterile swab dampened with normal saline.**
- **Once a sufficient number of patches are excised, apply them carefully to the wound. Do not place them too close together: further healing will bridge the gaps and this allows a larger area to be grafted.**

- **Dress the donor and graft sites with sterile vaseline gauze, then layers of swabs and a non-compressive bandage.**
- **The graft will take within 7 days, during which time the dressing should not be removed and the patient should remain as immobile as possible.**



**Figure 15 : DRESSING A BURN :  
STERILE TECHNIQUE, USE OF VASELINE-GAUZE**

## **FIGURE**



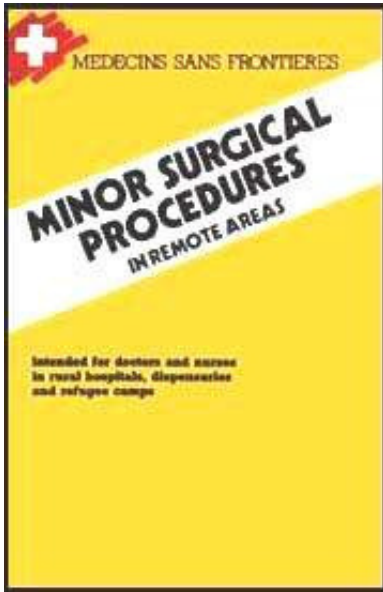
**Figure 16 :** FULL THICKNESS PATCH SKIN GRAFT : STERILE TECHNIQUE, TAKING OF DONOR PATCHES USING A FINE TOOTHED-FORCEPS AND A SCALPEL

## FIGURE

[Home](#) > [ar](#).[cn](#).[de](#).[en](#).[es](#).[fr](#).[id](#).[it](#).[ph](#).[po](#).[ru](#).[sw](#)

 **Minor Surgical Procedures in Remote Areas (MSF, 1989, 172 p.)**

  **Chapter 2: Infection of soft tissues**



**Abscess**

**Treatment of tropical myositis**

**Infections of the hand and fingers**

## **Minor Surgical Procedures in Remote Areas (MSF, 1989, 172 p.)**

### **Chapter 2: Infection of soft tissues**

#### **Abscess**

#### **Abscess anesthesia of abscesses and tropical myositis**

**Anesthesia of an abscess with lidocaine is not very effective. It is not possible to anesthetise the whole cavity and furthermore, the needle may spread the infection.**

**General anesthesia is preferable: ketamine IM, at the rate of 5mg/kg for exemple.**

**For superficial abscesses, use ethylene chloride: anesthetise the area and incise immediately (the anesthetic freezes the skin by evaporation). abscess**

**A collection of pus in the soft tissues. An abscess cavity is not accessible to antibiotics. Treatment is thus surgical only.**

## **Indications**

**Incision and drainage (I & D) should be performed once the abscess is "ripe" i.e. fluctuant upon gentle palpation.**

## **Material**

- **Sterile scalpel blade and handle**
- **Surgical gloves**
- **Plain curved forceps (Kelly forceps)**
- **Sterile corrugated drain**
- **Antiseptic s, e.g. chlorhexidine (+ cetrimide) solution (see table page 7).**


## **Technique**

### **Figures 17,18 and 19**

- **Scalpel: the correct way to hold a scalpel is between the thumb and forefinger with the handle resting against the palm. It should not be held as one holds a pen. The plane of the scalpel blade should be perpendicular to the plane of the skin.**
- **Incision: the free hand immobilizes the wall of the abscess between thumb and**

**forefinger. Incise in the long axis of the abscess with a single stroke to breach the skin. The incision should be long enough to allow insertion of an exploring finger.**

- **Take care not to incise too deeply if the abscess overlies major blood vessels (the carotid, axillary, humeral, femoral and popliteal regions). After breaching the skin, blunt dissect down to the cavity using Kelly's forceps.**
- **Explore the cavity with the forefinger, breaking any loculating adhesions and evacuating the pus. Abundant lavage of the cavity using a syringe filled with chlorhexidine (+ cetrimide) (see table page 7).**
- **Insert a drain, if possible fixing it with a single suture at the edge of the incision. The drain is withdrawn progressively then removed altogether after 3 to 5 days.**




**Figure 17**  
*POSITION OF THE HANDS* for incision of an abscess  
**FIGURE**



**Figure 18**  
EXPLORATION OF THE CAVITY WITH A FINGER, in order to break down loculations

**FIGURE**



**Figure 19**  
DRAIN FIXED TO THE SKIN

**FIGURE**

**Breast abscess**



## **Figure 20**

**Usually the abscess is superficial but deep ones, when they occur, are more difficult to diagnose and treat.**

**Early in the infection, before the infection loculates (mastitis), it is possible to treat medically: antibiotics, anti-inflammatories, hot compresses, constricting bandage to reduce lactation in the affected breast and expression of milk to avoid engorgement.**

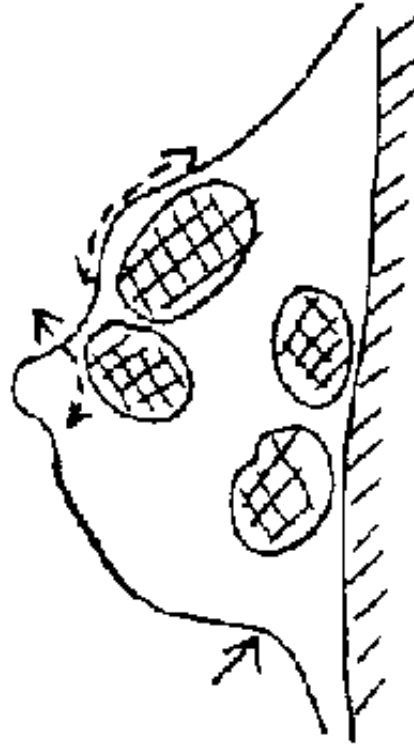
**Fluctuation occurs early in superficial infections and later for deeper infections.**

### **Material**

**Same material as for other abscesses.**

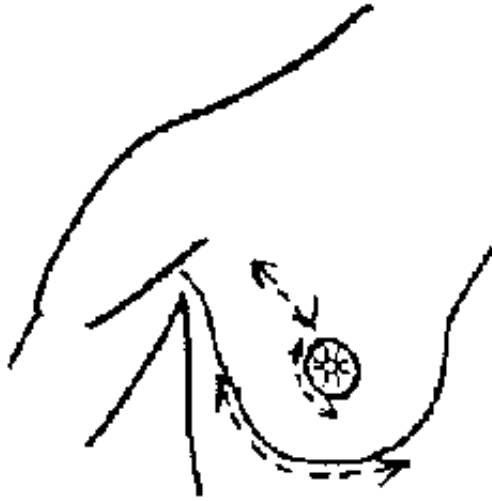
### **Technique**

- **Radial incision for superficial abscesses, peri-areolar for abscesses near the nipple (Figure 21).**
- **Submammary incision for deep abscesses (Figure 22).**
- **Gentle exploration with finger or forceps to break down loculations (Figure 23).**
- **Abundant lavage with chlorhexidine (+ cetrimide) solution (see table page 7).**
- **Insertion of a large drain.**



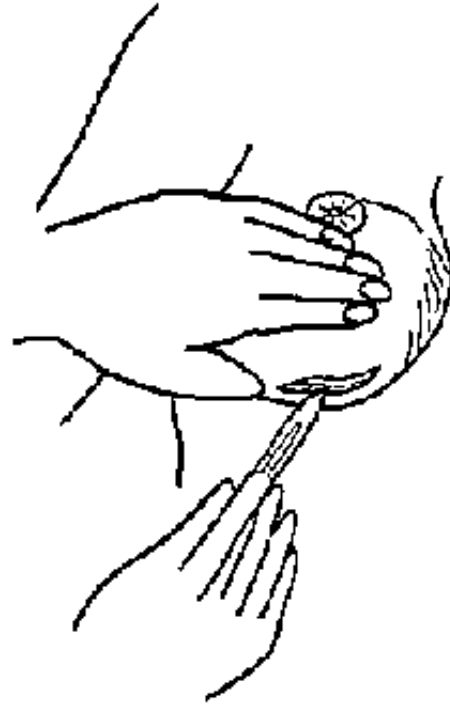
**Figure 20**  
**Common sites for breast abscess**

**FIGURE**



**Figure 21**  
Incisions : radial, peri-areolar  
or submammary

**FIGURE**



**Figure 22**  
SUBMAMMARY INCISION

**FIGURE**

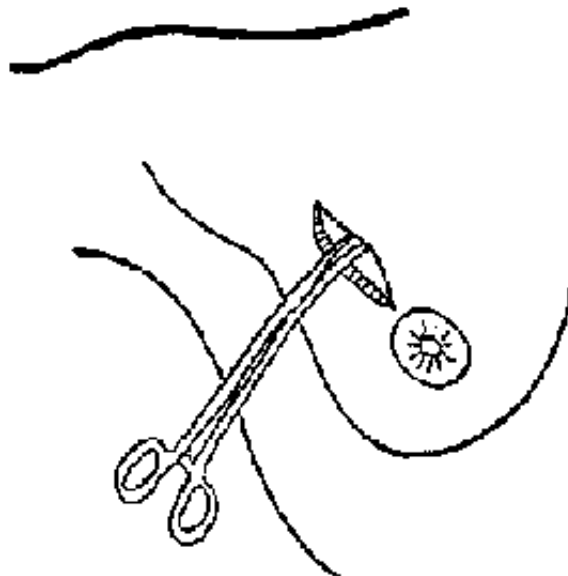



Figure 23  
GENTLE EXPLORATION with a finger or forceps  
**FIGURE**

## Parotid abscess

**The incision is a risk to the branches of the facial nerve. Consequently, the incision should be over the caudal part of the abscess and parallel to the lower border of the maxilla.**



**Figure 24**  
HORIZONTAL INCISION for parotid abscess  
**FIGURE**

## **Treatment of tropical myositis**

### **Anesthesia**

### **Treatment of myositis**

### **Example: myositis of the quadriceps**

**Infection and eventually abscess formation within muscle sheaths.**

**At the start of infection, when the muscle is swollen, hot and painful, medical treatment may prevent abscess formation: immobilize, give antiinflammatory medication (Indomethacin (PO): 75 mg/d in 3 divided doses x 5 days), and**

**antibiotics (ampicillin (PO): 4 g/d in 4 divided doses x 7 days for an adult).**

## **Indications**

**When the swelling becomes fluctuant conduct an exploratory puncture with a largebore needle which, if the diagnosis is correct, will produce thick pus (Figure 25).**

## **Material**

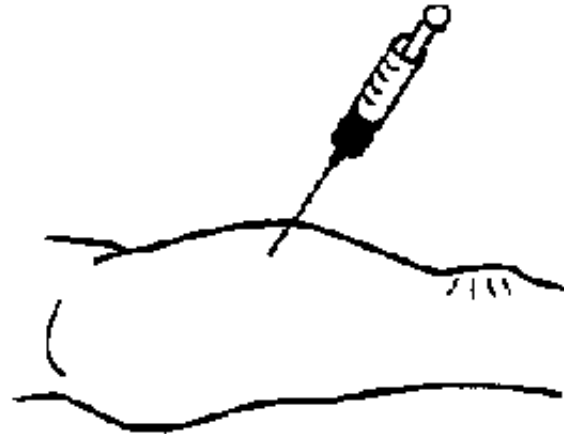
**The same as for an abscess.**

## **Technique**

**(Figures 25, 26, 27, 28, 29)**

- **Generous skin incision, avoiding underlying neurovascular bundles, and incision of the fascia and muscle sheath.**
- **Blunt dissection with Kelly forceps or rounded scissors; push the closed instruments into the muscle as far as the abscess cavity and gently open them and withdraw.**
- **Explore with a finger to break the adhesions and evacuate the pus.**
- **Lavage with chlorhexidine (+ cetrимide) (see table page 7).**
- **If possible, place a counter incision on the skin near the edge of the abscess, cutting down on a finger that is inserted deep in the cavity.**

- **Pass a strip of corrugated drain between the two incisions.**
- **Fix the drain with a suture to the edge of the incision and withdraw around the 5th day.**



**Figure 25**  
**EXPLORATORY PUNCTURE**

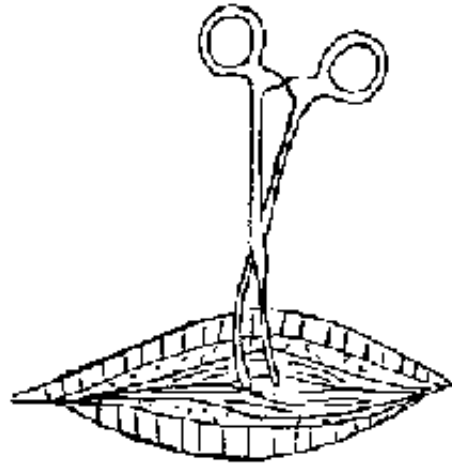
**FIGURE**



**Figure 26**  
**GENEROUS INCISION**

**FIGURE**





**Figure 27**  
*BLUNT DISSECTION OF MUSCLE USING KELLY FORCEPS : insert closed then withdraw slightly open.*

**FIGURE**




Figure 28  
COUNTER INCISION FOR BRAIN, cutting down onto a finger inserted deep  
in the cavity.

## FIGURE



**Figure 29**  
*DRAINAGE* with a corrugated drain passing through the two incisions.

## **FIGURE**

### **Myositis of the psoas muscle**

**If the abscess is on the right side, the clinical signs are the same as for appendicitis with pain in the right iliac area.**

**Treatment requires surgical intervention as far as the peritoneum. This is the only way to make the diagnosis and consequently the operator must be able to carry out an appendicectomy if required.**

**In the case of a psoas abscess, once the peritoneum has been reached, it should be separated, not opened and the psoas should appear behind. Open the sheath (blunt dissection with rounded scissors; insert closed then withdraw slightly open) and release the pus. Clean and drain as with other abscesses.**

### **Infections of the hand and fingers**

## **Paronychia**

**Infection of a finger is a paronychia.**

### **Indications**

**Antibiotics, frequently prescribed during the acute phase, retard the collection of pus and consequently drainage. Patients are seen most often during the acute phase.**

### **Superficial paronychia**

### **Material**

**Scalpel, pair of rounded scissors, non toothed dissecting forceps, gloves, sterilized drapes, and equipment for a local anesthetic.**

### **Anesthesia**

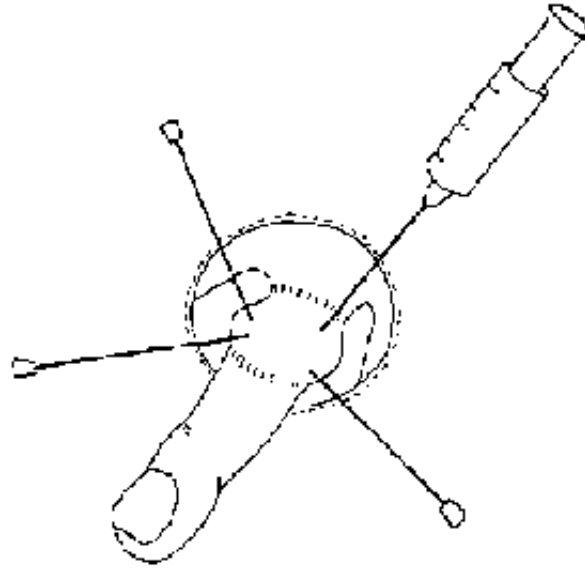


Figure 30 :  
Anesthesia - RING BLOCK

### Figure 30

**Ring block with lidocaine 1%, or anesthetise the skin with ethylene chloride.**

#### **Technique**

- **Paronychia at the edge of the nail**

**Lift and separate the edge of the nail with a scalpel at the point of oedema and inflammation; pus will escape. Apply daily dressings.**

- **Subungual paronychia**

**The nail is elevated by pus between the nail and the tip of the finger. Cut a triangle between the nail bed and the pulp and excise the pus. Apply daily dressings.**

- **Peri-ungual paronychia**

**The edge of the nail and the base are separated by the abscess. Incise the skin at the nail base and continue along the nail edge separating the skin from the nail base. Lift part of the nail, that covering the abscess, but leave the part which protects the unguis phalanx and assists healing. Apply daily moist dressings.**

- **Paronychia on the dorsum of the finger**

**Almost always occurs on the index finger. Incise with a scalpel and dress daily. Give antibiotics (e.g. ampicillin: 4 g/d for an adult, in 4 divided doses for a minimum of 5 days) to avoid the spread of infection and risk to the extensor tendon.**

### **Subcutaneous paronychia**

- **Paronychia of the finger pulp: deep infection**

**One or two lateral incisions, on the dorsal and ventral surfaces of the finger, avoiding the vascular/nerve bundles. Insert a small drain for two days. Apply daily moist dressings.**

- **Paronychia of the two first phalanges**

**One or two lateral and dorsal incisions at the superior border of the two commissures, avoiding the vascular/nerve bundles. Apply daily moist dressings.**

### **Osteitis of the finger**

**Suspect a persistent fistula or even a fistula communicating with bone when an incision demonstrates the presence of a sequestration. Bony excision must be minimal; it is necessary to limit excision to the sequestered bone and to avoid amputation.**

**Prescribe a large dose and a long course of antibiotics (ampicillin: 4g/day for an adult, for a minimum of 4 weeks).**

**Immobilise in flexion with a splint.**

**Tenosynovitis of the finger**

**Collection of pus in the sheath of the flexor tendon of the finger.**

**Diagnostic**

**The finger is bent with pain running along its length.**

**Material**

**Surgical kit**

**Anesthesia**

**General (Ketamine) or local/regional.**

**Technique**

- **First make a vertical palmer incision of 2.5 cm at the head of the metacarpal.**

- **Shield and protect the vascular/nerve bundles.**
- **Identify the cul-de-sac of the dilated sheath and incise on both sides. Clean with chlorhexidine (+ cetrimide) solution (see table 1).**
- **Place closed forceps into the incision through to the skin on the opposite side and make a counter incision with a scalpel.**
- **Pass a drain between the two incisions. This drain remains until the swelling disappears.**
- **Immobilise with a splint and prescribe antibiotics (e.g. ampicillin : 4 g/d for an adult in 4 divided doses for at least 8 days).**
- **Apply daily dressings.**



[Home](#) > [ar](#).[cn](#).[de](#).[en](#).[es](#).[fr](#).[id](#).[it](#).[ph](#).[po](#).[ru](#).[sw](#)

 **Minor Surgical Procedures in Remote Areas (MSF, 1989, 172 p.)**

  **Chapter 3: Catheterisation and drainage**

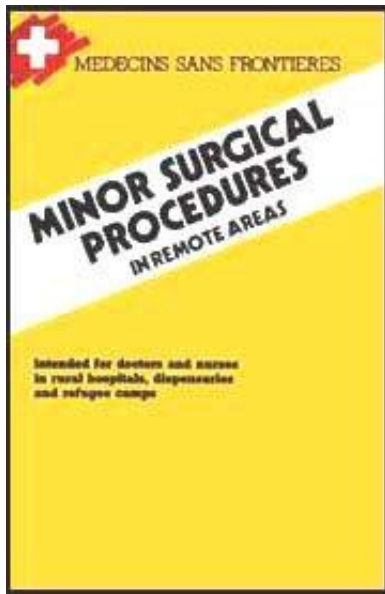
 **Catheterisation of large veins**

 **Lumbar puncture**

 **Pleural puncture**

 **Thoracic drainage**





-  **Pericardial puncture**
-  **Drainage of ascites and intra-peritoneal perfusion**
-  **Puncture and drainage of the knee**

## **Minor Surgical Procedures in Remote Areas (MSF, 1989, 172 p.)**

### **Chapter 3: Catheterisation and drainage**

#### **Catheterisation of large veins**

**Introduction of a percutaneous catheter into a large vein (jugular or femoral).**

#### **Indications**

**Peripheral venous collapse requiring rapid vascular perfusion.**

#### **Material**

**Large bore needles and catheters (16 to 24 G) and intravenous fluids are needed.**

## **Technique**

### **External jugular vein**

- **Lower and turn the patient's head to the opposite side of the chosen vein.**
- **Rigorous asepsis: clean with polyvidone iodine (see table page 7).**
- **Compress the base of the neck to dilate the vein which crosses the sternomastoid muscle.**

### **Internal jugular vein**

- **Gently lower and turn the patient's head to the opposite side of the chosen vein.**

**Rigorous asepsis: clean with polyvidone iodine and use sterile gloves.**

**Place a large bore needle and catheter (e.g. 16 G for an adult) on a syringe.**

**Puncture the head of the triangle formed by the two heads of the sternocleidomastoid and the clavicle.**

**Direct the needle behind, parallel to the median line (ATTENTION: the CAROTID !) and at an angle of 30° to the horizontal.**

**Gently advance the needle while aspirating on the syringe. ATTENTION: do not advance too far under the clavicle because of the risk of a pneumothorax.**

**When blood appears, ask the patient to hold his/her breath, and slowly advance**

**the catheter.**

**- Apply a sterile dressing.**

## **Femoral Vein**

- **The technique is easier than for the internal jugular vein but the region is septic.**
- **Rigorous asepsis.**
- **Place a large bore catheter on a syringe.**
- **Mark the crural arc; the line in the groin joining the antero-superior iliac spine and the spine of the pubis (the spine of the pubis is marked by palpating the superior border of the bone).**
- **Mark the edges of the femoral artery in the crural arc and fix the vessel beneath two fingers of the left hand.**
- **In adults, puncture 1cm on the inside of the wall of the artery and 2cm below the crural arc.**
- **Puncture almost vertically and a little obliquely while continuously aspirating on the syringe.**
- **If bone is struck, withdraw while continuing to aspirate.**
- **When in the vein, gently lower the syringe towards the buttocks and advance the catheter. Ensure that the catheter is in the vein by aspirating blood into the**

**syringue and then remove the introducer.**

- **Apply a sterile dressing.**
- **In the case of an arterial puncture, apply pressure for 10 minutes.**

## **Lumbar puncture**

**Removal of cerebrospinal fluid (CSF) for diagnostic purposes.**

### **Indications**

**Suspicion of meningitis (fever, vomiting, nuchal rigidity.)**

### **Contraindications**

**Intracranial hypertension, Pott's disease.**

### **Material**

**Lumbar puncture needle with a stylette (for adults, 20G; for children, 23G).**

### **Position of the patient**

**If possible, the patient should be sitting, back rounded, vertebral column rectilinear, head bent, chin on the sternum, and arms across the knees. If this is not possible, put the patient in the fetal position with back rounded and head flexed.**

## **Technique**

- **Cleanse the lumbar region with polyvidone iodine(see table page 7) and if possible use sterile gloves.**

**Mark the spinous process of the 4th lumbar vertebra by a horizontal line between the superior iliac crests (in adults, the spinal cord descends to the second lumbar vertebra; in children, it descends to the 4th).**

- **Place the tip of the left index finger on this spine.**
- **Inject exactly between the two spines (L3 and L4 or L4 and L5) rapidly traversing the skin, then horizontally or obliquely towards the head.**
- **In adults, at a depth of 3 to 4 cm, there is resistance due to the transverse ligaments: if a needle is advanced a little further, the epidural space is reached.**
- **Remove the stylette and if the puncture is successful, liquid will appear. Do not aspirate the syringe, but collect the liquid in a bottle.**
- **Replace the stylette in the needle and withdraw together, then compress the puncture wound with a dressing of polyvidone iodine (see table page 7).**
- **After the lumbar puncture, confine to bed for 24 hours.**

## **Incidents**

- **Failed puncture**

**Start again (the axis of the needle is incorrect, there has been contact with bone, the position of the patient is incorrect, the needle has not been advanced sufficiently).**

- **Bloody puncture**

**Start again (puncture of a peridural vein, or subarachnoid hemorrhage).**

- **Sudden pain in the inferior limb**

**Occasionally a caudal nerve is hit; do nothing but ensure that the CSF is examined.**

## **Pleural puncture**

**Puncture between the two pleural layers.**

## **Indications**

**Drainage of pleural fluid for exploratory and diagnostic purposes.**

## **Material**

**The same material as for a lumbar puncture: needle with stylette 20 to 23G.**

## **Technique**

**Rigorous asepsis: clean the area with large quantities of polyvidone iodine (see table 1), sterilised equipment and sterile gloves if possible.**

**The patient should be seated, bending forward with hands on knees.**

**Place a long, large bore needle on a syringe (the wall thickness is about 3cm).**

**For an exploratory puncture, avoid the cardiac region, the section above the axillary crease, and do not inject below the 9th rib.**

**Puncture the superior brim of the inferior rib marked with the index finger of the left hand.**

**Gently advance the needle perpendicular to the surface, while aspirating the syringe, until fluid is collected. If the puncture fails, remove the needle aspirating all the time, and start again in an adjacent space.**

**In the case of a puncture for drainage of fluid or for diagnostic collection, enter the 8th intercostal space in the posterior axillary line. When the fluid has been collected, connect the needle to a large diameter drainage tube (a perfusion tube) which can be clamped with forceps and attached to a large aspirating syringe (30 to 50mls).**

**Drainage of fluid must be slow and not more than 700 to 800ml per episode.**

**ALWAYS ASPIRATE while removing the needle and compress the puncture point with a sterile dressing.**

## **Accidents**

- **Pulmonary edema and syncope: rarely.**
- **Pneumothorax created by the entry of air at the time of puncture; prevented by ensuring a tight fit between the needle and syringe and by ensuring that continuous aspiration occurs as the needle is withdrawn.**

- **Accidental puncture of the vascular/nerve bundles due to a puncture at the inferior rather than the superior border of the rib.**

## **Thoracic drainage**

**Drainage of liquid or air between the two pleural layers.**

### **Indications**

**Pneumothorax, hemothorax, empyema.**

### **Material**

- **For local anesthetic**
- **Drapes and sterile gloves**
- **2 Kelly forceps, 1 scalpel**
- **1 thoracic drain with trochar (type Monod) or a tubular catheter**
- **Connecting pipe**
- **Bottle containing an antiseptic solution (chlorhexidine (+ cetrimide), see table page 7)**
- **Non resorbable suture material (Dec 3 or 2/0).**

### **Technique with or without a trochar**



## **Figure 54**

- **Patient in sitting position**
- **Disinfect the skin with polyvidone iodine (see table page 7).**
- **Puncture point: on the anterior axillary line, posterior to pectoralis major, above the nipple, which corresponds to the 4th intercostal space, 4 finger breadths from the axilla, at the superior edge of the inferior rib. (This point is considered the least dangerous, avoiding organ puncture. Theoretically it is too low for treatment of a pneumothorax and too high for treatment of a purulent pleural discharge).**
- **ATTENTION: there is often a tendency to longer the needle and therefore to risk a hepatic or splenic puncture.**
- **Inject local anesthetic (lidocaine 1 %) at the site of the puncture, cross all tissue plains until the discharging site is reached and then remove the needle while aspirating.**
- **Make a transverse incision of 1 cm with a scalpel in the cutaneous and subcutaneous tissues at the superior border of the inferior rib.**

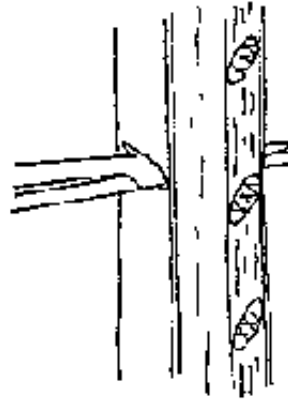
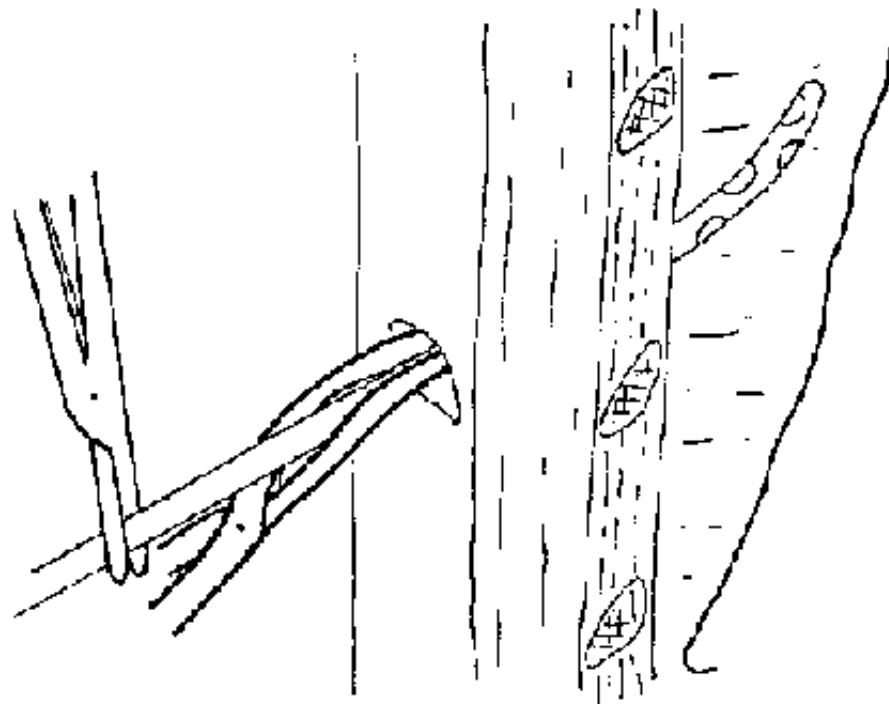


Figure 54  
Separate the fibres of the  
intercostal muscles with  
Kellys forceps

## FIGURE

### Drain without a trocar

- **Introduce a pair of Kelly forceps into the incision at the smooth border of the rib and gently separate the intercostal muscle fibres, then perforate the pleura. Next, introduce the drain (with intrapleural perforations) between the clasps of the Kellys. ensuring that the other end of the drain is clamped.**
- **Introduce the drain until it is estimated that the perforations are within the pleura, knowing that the thickness of the well is about 3 cm (figure 55).**



**Figure 55**

Introduction of the drain between the clasps of the Kelly forceps

## **FIGURE**

### **Drain with trocar**

### **Figures 56, 57, 58**

- **Push firmly, until the pleura is reached, rotating the trocar with one hand and using the index finger on the trocar as a guard to prevent rapid entry.**
- **Remove the stylette and cover the end of the trochar with a finger. Then**

## **introduce the clamped drain.**

- **Remove the trocar as far as the chest wall and clamp the drain above the trocar.**
- **ATTENTION:** during the few seconds when air can enter through the trochar, ask the patient to stop breathing in order to prevent air entry.
- **Attach the drain to a drainage tube connected by an airtight seal to a bottle containing an antiseptic solution. The tube should be placed in the solution.**

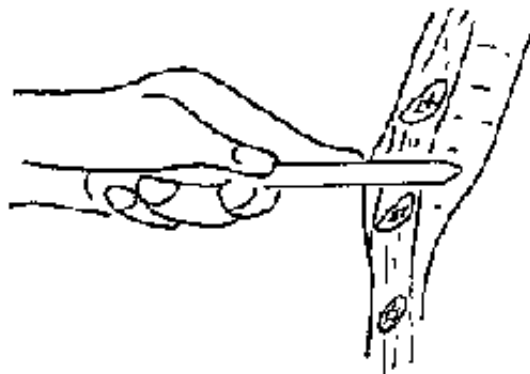
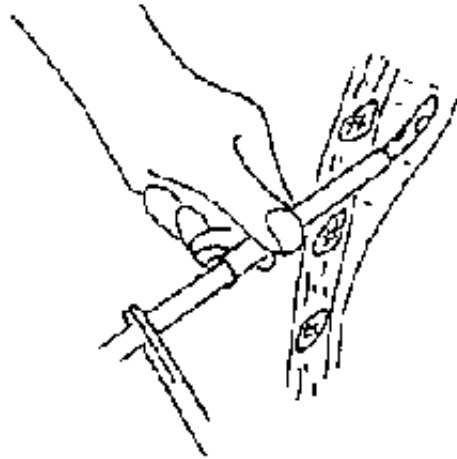


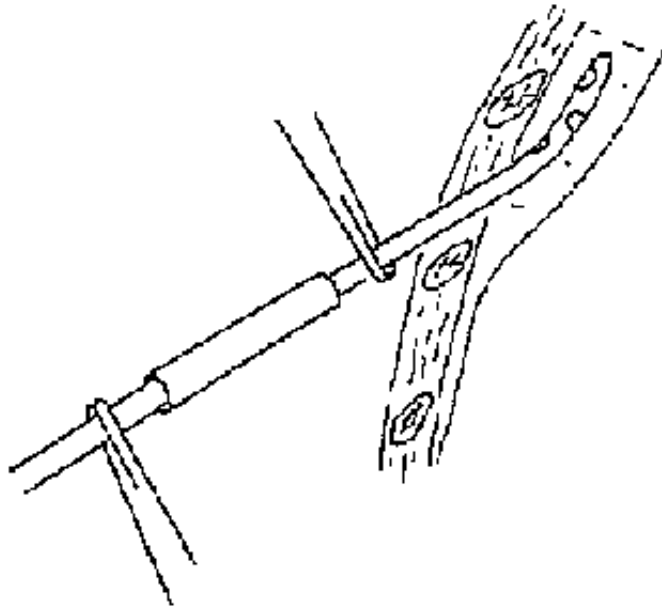
Figure 56

Index finger on the trocar acting as a guard

## **FIGURE**



**Figure 57**  
Introduction of the drain  
**FIGURE**



**Figure 58**  
Withdrawal of the trocar

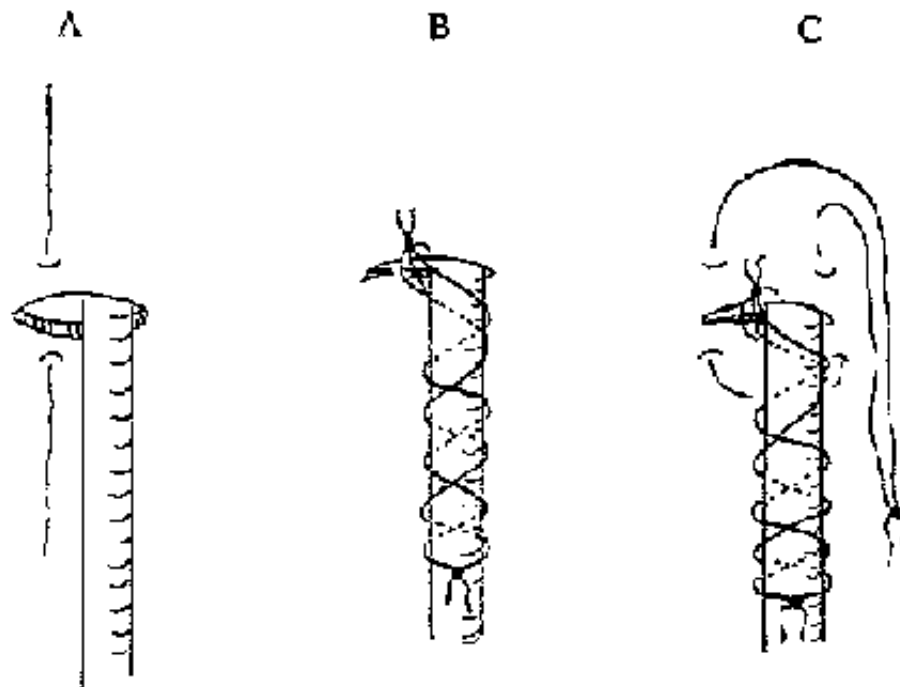
## **FIGURE**

**The drain must be fixed to the skin:**

- **Use non resorbable suture material (Dec 3 or 2/0).**
- **Suture the drain to one of the edges of the wound and make a knot to ensure that the connection is airtight. Then criss-cross the suture material along the drain and fasten with a knot.**

**Additional suture**

**Attach another suture to the skin and around the drain, leave it long and knotted.**



**Figure 59**  
*FIX THE DRAIN to the skin (A and B) and the additional suture (C)*

## **FIGURE**

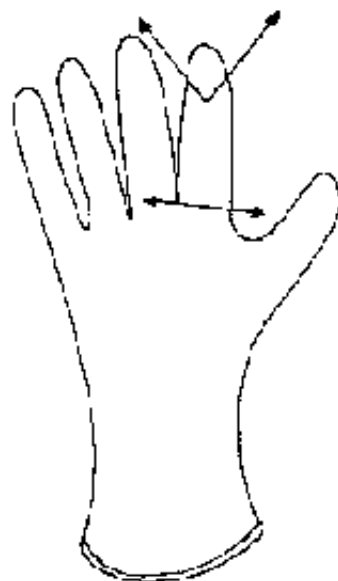### **Anti-reflux system**

#### **Figures 60, 61**

**A sterilised anti-reflux valve is normally used, but if not available in the case of a pneumothorax, the end of a surgical glove attached to the drain acts as a valve.**



**Figure 60**  
**ONE WAY VALVE**  
**FIGURE**

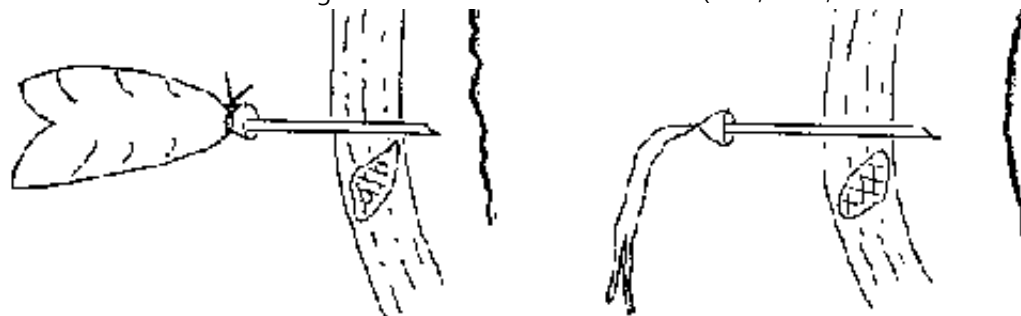


Inspiration

Expiration



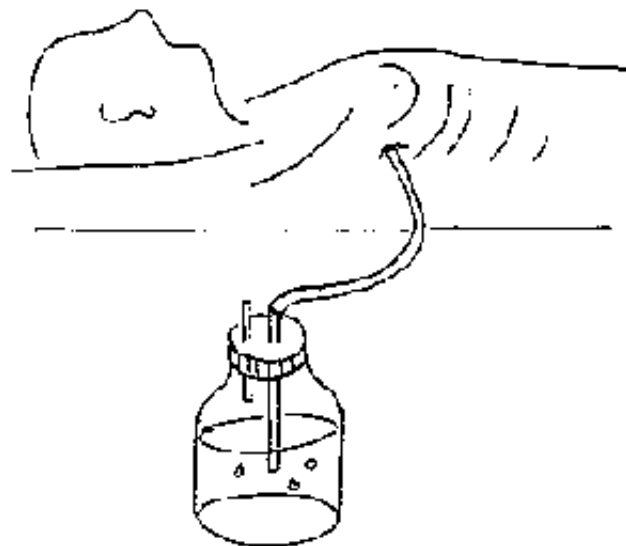




**Figure 61**  
*ANTI-REFLUX SYSTEM* using the finger of a glove attached to the drain

## FIGURE

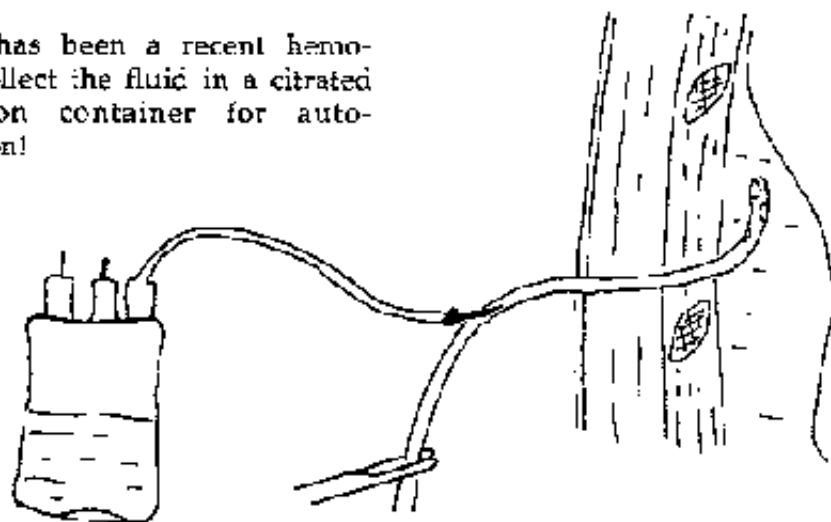
### *Drain attachments*



**Figure 62**  
The drain is attached to an airtight sterilized bottle containing an antiseptic liquid.

**Figure 63**

If there has been a recent hemothorax, collect the fluid in a citrated transfusion container for auto-transfusion!

**FIGURE**

## Removal of the drain

### When the draininage is complete:

- **Cut the knot of the additional suture and the knot fixed to the drain.**
- **Make a bow with the additional suture.**
- **Ask the patient to stop breathing while an assistant removes the drain.**
- **Tie the knot and the additional suture will close the puncture wound.**

## **Pericardial puncture**

**Puncture between the two layers of the pericardium to evacuate fluid (blood or serous).**

### **Indication**

**Tamponade, massive cardiac collapse.**

### **Diagnostic signs**

- **Dyspnea, anxiety, syncope.**
- **Distended jugular veins.**
- **Tachycardia and disappearing heart sounds.**
- **Falling blood pressure, reduce difference between systolic and diastolic blood pressure, systolic pressure falling with deep inspiration.**

### **Material**

- **Short bevel catheter of 16 G**
- **50 ml syringe**
- **Sterile drapes with a hole**
- **Sterile gloves**

- **Polyvidone iodine (see table page 7)**

## **Technique**

- **Rigorous asepsis.**
- **Fix the needle to the syringe.**
- **Introduce the needle to the left of the xyphoid process at an angle of 45° to the skin.**
- **Point the needle towards the right shoulder advancing and aspirating until blood appears.**

## **Incident**

**Perforation of the inferior wall of the heart: withdraw the needle a little.**

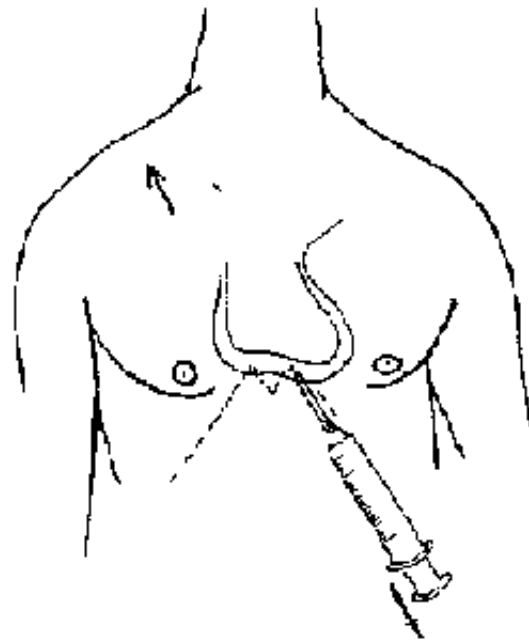
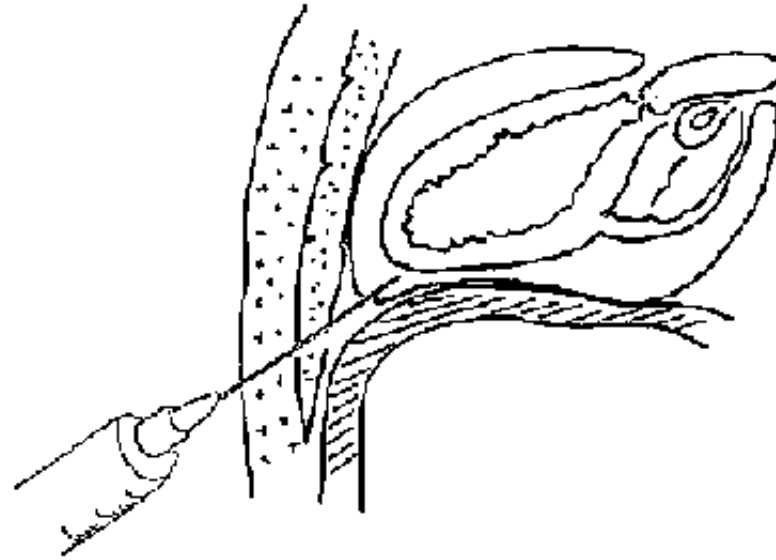


Figure 64

At the left edge of the xyphoid, introduce the needle at 45° to the skin, directed towards the right shoulder.

**FIGURE**



**Figure 65**  
Advance the needle while aspirating

## **FIGURE**

### **Drainage of ascites and intra-peritoneal perfusion**

- **Drainage of fluid in the peritoneum** **Injection of intra-peritoneal perfusion**

#### **Indications**

- **Drainage of ascitic fluid is indicated principally for diagnostic purposes or when respiration is impaired. Drain slowly. Attach a drainage tube and container to the trochar, do not remove more than 1 liter per episode.**
- **Intra - peritoneal perfusion: indicated when there is difficult access to a vein, to avoid losing time while waiting for venous access, for example in children with**

**acute dehydration. Do not perfuse more than 70 ml/kg, perfuse slowly and use only sodium chloride or ringer lactate.**

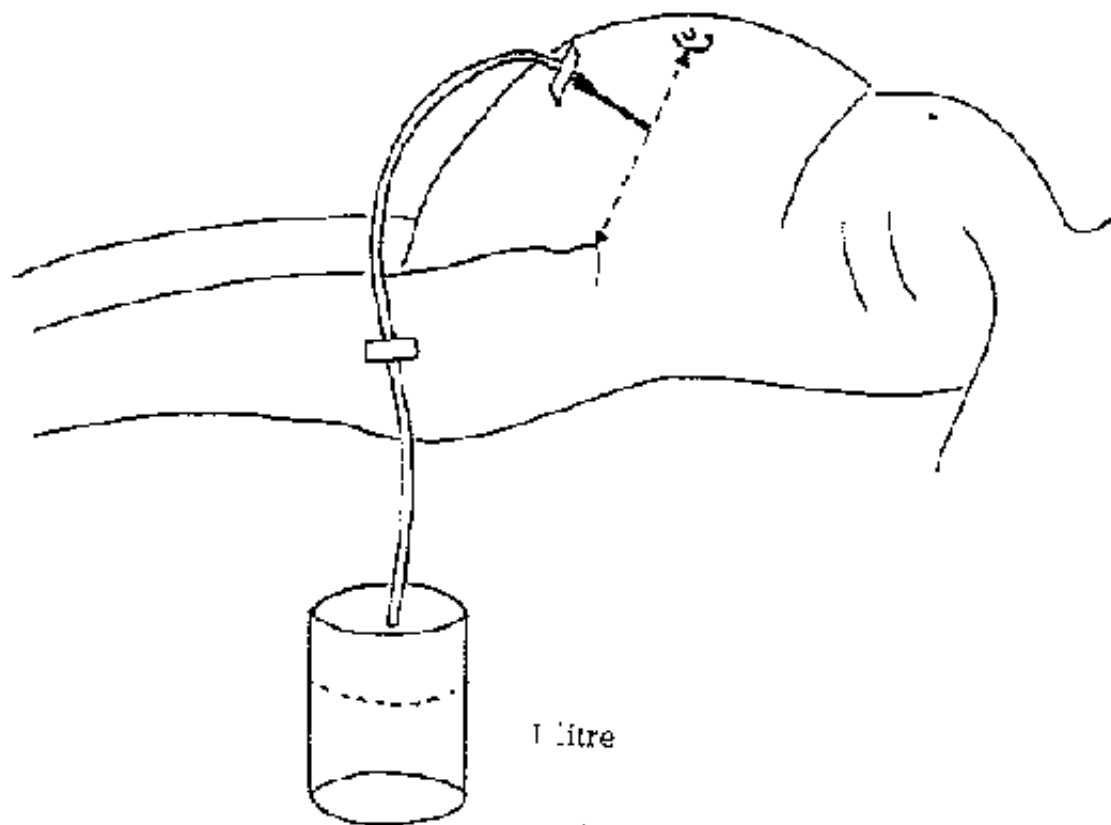
## **Material**

**Large trocar or short large bore catheter (18 G for exemple).**

## **Technique**

### **Figure 66**

- **Rigorous asepsis: clean the abdomen with polyvidone iodine (see table page 7).**
- **Single puncture, perpendicular to the abdomen, on a line joining the umbilicus and the anterior superior iliac spine, usually on the left, to avoid perforation of the cecum; on the right in the case of massive splenomegaly.**



**Figure 66**  
*DRAINAGE OF ASCITES*  
At a point mid-way between the umbilicus  
and the anterior superior iliac spine

**FIGURE**



## **Puncture and drainage of the knee**

### **Drainage of fluid in the articular cavity of the knee.**

#### **Indications**

- **Painful hemarthroses in cases of knee torsion: wait 24 to 48 hours before puncture and drainage to allow the hematoma to collect and to prevent recurrence.**
- **Hyarthrosis: injection of diagnostic fluid or removal of post-trauma serous fluid.**

**If pus is found in the joint space, surgical drainage is necessary.**

#### **Material**

**Large bore needle and syringe or trochar.**

#### **Technique**

**Figures 67, 68**

- **Rigorous asepsis: drapes and sterile gloves, clean with polyvidone iodine (see table page 7).**
- **Puncture with a trocar or large needle at an angle above and lateral to the knee cap, and 1/2 cm above and behind.**
- **Advance at an angle of 45° to the horizontal and sagittal planes, and push the**

**needle behind the knee cap.**

- **To empty the cavity, squeeze the quadriceps muscle with the left hand while aspirating on the syringe with the other hand.**

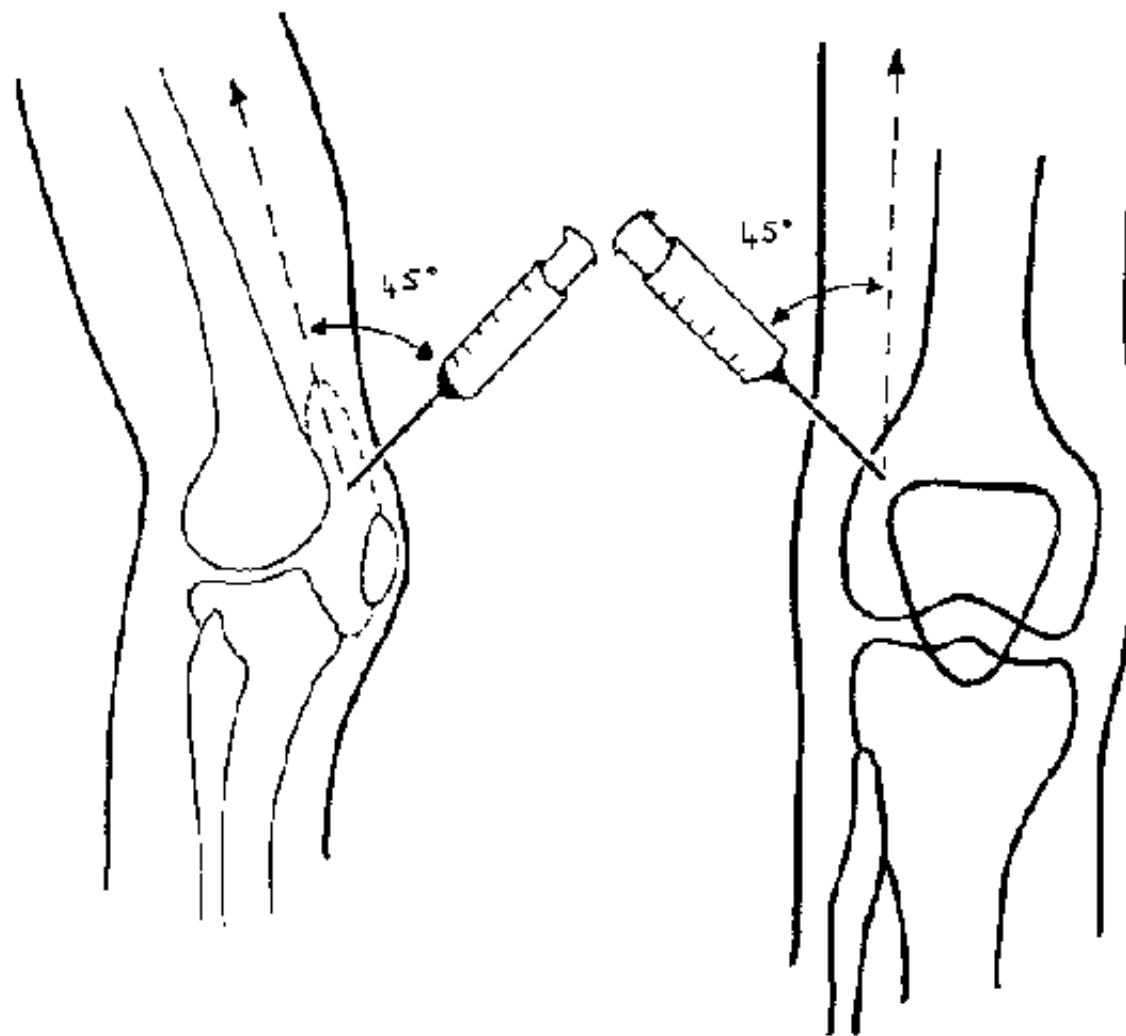


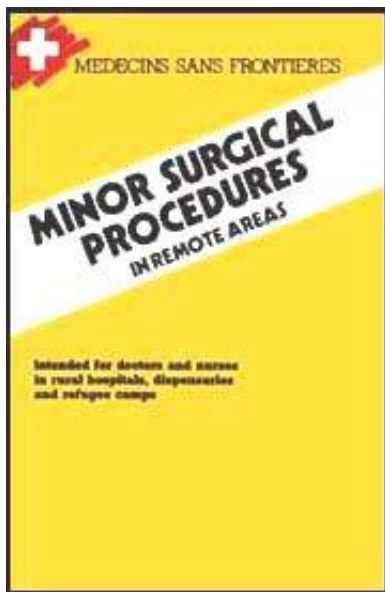
Figure 67

Figure 68

PUNCTURE OF THE KNEE  
At an angle above and behind the knee cap

**FIGURE**

[Home](#) > [ar](#).[cn](#).[de](#).[en](#).[es](#).[fr](#).[id](#).[it](#).[ph](#).[po](#).[ru](#).[sw](#)



 **Minor Surgical Procedures in Remote Areas (MSF, 1989, 172 p.)**



**Chapter 4: ent procedures**



**Epistaxis**



**Ear drainage**



**Dental extraction**

**Minor Surgical Procedures in Remote Areas (MSF, 1989, 172 p.)**

**Chapter 4: ent procedures**

**Epistaxis**

**Bleeding from the nose.**

**Material**

**Wick of vaseline gauze**

**Fine dissecting forceps**

## **Urinary catheter (sound) with n° 12 balloon**

### **Technique**

#### **Figures 69, 70**

**First, introduce the vaseline gauze, not more than 2 cm, as far into the nose as possible, with dissecting forceps, and try to fold the gauze in pleats from behind forwards.**

**Pack the bleeding nasal cavity and hold it in place with an adhesive tape.**

**If bleeding continues despite the pack, posterior bleeding is occurring: introduce a Foley catheter (n°12) as far as the oropharynx, inflate the balloon with 10 to 15 ml of air (Figure 69), and pull back until it abuts on the posterior pharyngeal wall. Then, introduce the vaseline gauze as before. Maintain the catheter and the gauze mesh with an adhesive tape (Figure 70).**

**If bleeding continues, it is coming from the other nostril.**

**The pack must remain for at least 3 days.**





Figure 69

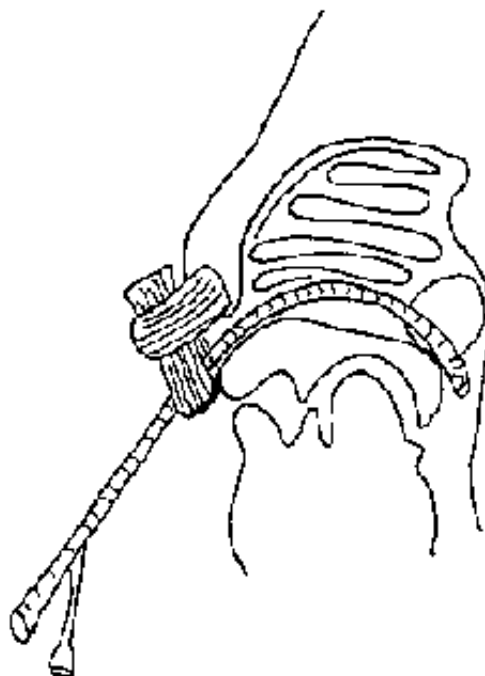


Figure 70

PACK FOR POSTERIOR EPISTAXIS

**FIGURE**

## Ear drainage

## **Incision of the tympanic membrane.**

### **Indication**

**Acute otitis with fever, intense pain, and an inflamed distended non-perforated tympanic membrane.**

### **Material**

**Drainage needle**

**Otoscope with a light or a speculum with a head-light.**

### **Technique**

**Figures 71, 72**

**While viewing the membrane, and without anesthesia, make a radial incision in the posterior-inferior quadrant with a stylet or a special lancet.**

**Aspirate the pus with a soft catheter, gently removing the serous fluid and pack gently with cotton.**

### **Antibiotic therapy**

#### **Systemic:**

**Ampicillin if less than 5 years of age: 100 mg/kg/day PO x 3 -10 days**

**Phenoxymethyl penicillin / Penicillin V older than 5 years of age:**

**Adult : 3 x 2 tablets/day (tablets of 400.000 U)**

**Child : 50 to 100.000 U/kg/day x 5 to 10 days, or procaine penicillin or PPF**



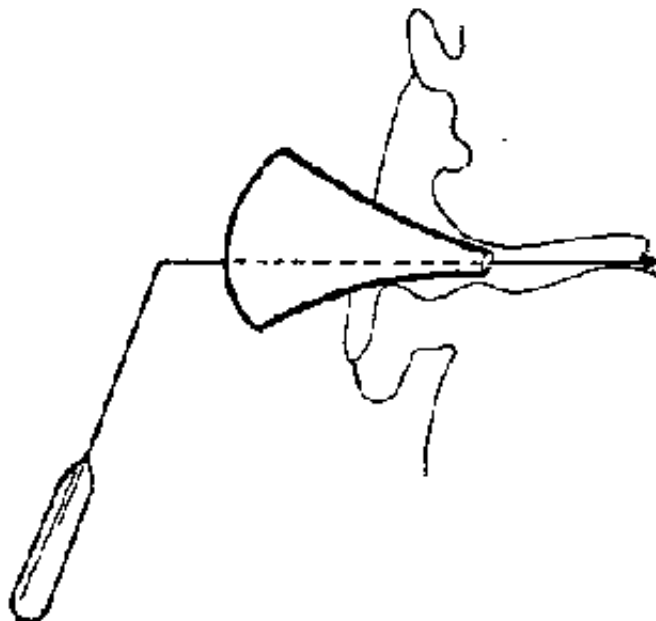


Figure 71




Figure 72

**EAR DRAINAGE:** incision in the posterior inferior quadrant of the tympanic membrane

## **FIGURE**

**100.000 U/kg/day x 3 days, followed by penicillin V during 4 to 6 days.**

**Erythromycine for those allergic to betalactamines:**

**Adult : 1 g in 3 divided doses/day x 10 days**

**Child : 50 mg/kg/day in 3 divided doses/day x 10 days**

**Dental extraction**

**Always remember that a tooth is not "pulled" but gently extracted ! It is a surgical procedure and therefore strict surgical etiquette must be followed to prevent serious complications (fractures of the bone or teeth, hemorrhage, infection).**

**Pre-operative examination**

**General history and examination of the patient**

**Search for potential contra indications to anesthesia.**

**Examination of the mouth**

**The teeth are numerous, but each is an important individual structure, and each must be preserved if possible. The decision to extract a tooth must be taken for immediate therapeutic or curative reasons.**

**Teeth possibly requiring extraction:**

- **acute (toothache) or chronic inflammation of the pulp,**
- **necrosis of the pulp,**
- **infection (abcess, cellulitis),**
- **teeth with dead roots.**

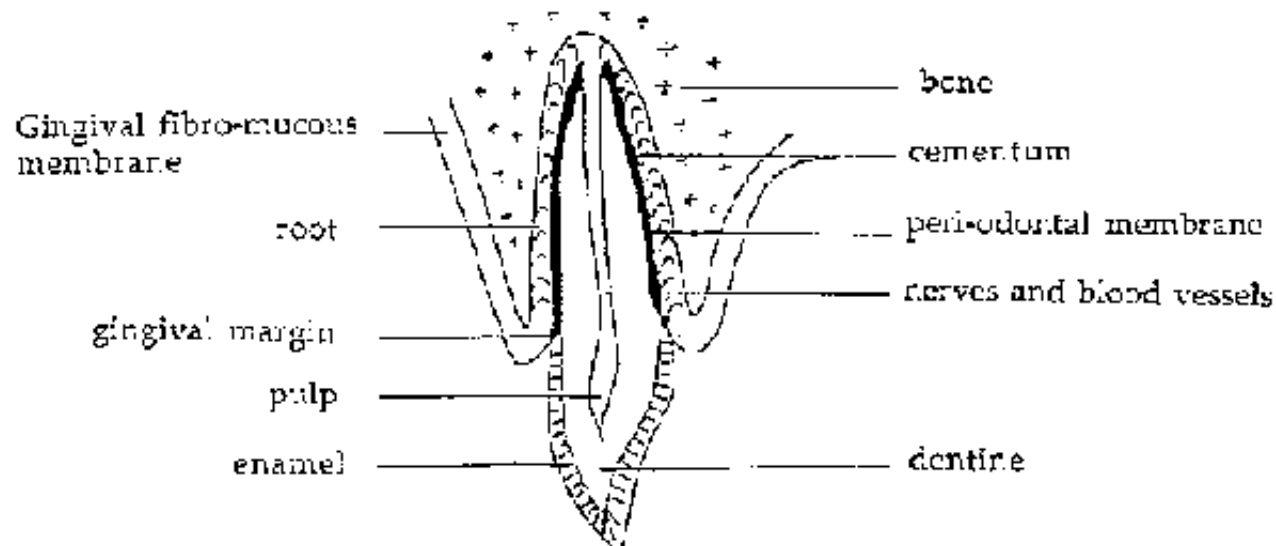


Figure 73  
ANATOMY OF A TOOTH

## FIGURE

### Premedication

Required for each general anesthetic.

**In cases with associated cellulitis: prescribe an antibiotic for 6 days and an antiinflammatory (ampicillin: 2 g/day in 3 doses and indomethacin: 75 mg in 3**

**doses/day for an adult). Do not extract the tooth until the following day, this will allow the inflammation to subside making the anesthetic more efficacious.**

## **Operation technique**

### **Preparation of the patient**

#### **Position of the patient:**

- Sitting, for lower teeth.**
- Lying, for upper teeth.**
- Always place the head on a firm surface to prevent movement.**

**Surgical drapes: A clean drape around the neck is recommended.**

**Position of the operator: - Facing the patient for the upper teeth and for teeth on the lower left side. - Behind the patient's head for teeth on the lower right side.**

## **Anesthesia**

### **Material**

**A cartridge syringe (carpule) with plunger, to avoid intravascular injection.**

**Sterilized needles for cartridges type S. Neved: - short n°17/23 for local injection  
- long n°17/42 for local regional injection**

**Cartridge without vasoconstrictor - scandicaine 3 % (no allergic reactions) -  
lidocaine 2 % (more toxic than scandicaine)**

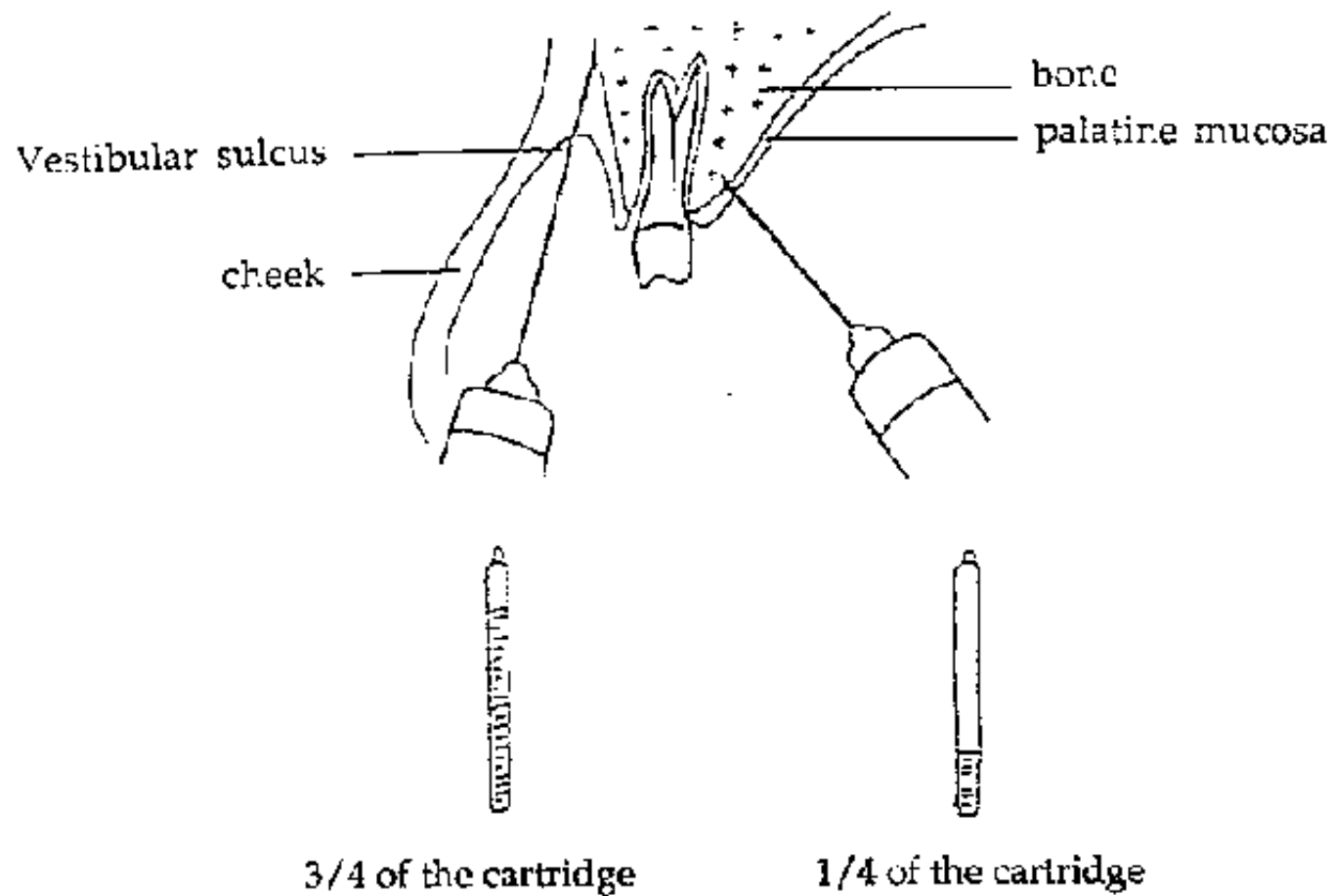
## **Maxilla**

**Conduct a local anaesthetic opposite the tooth of interest in the following order:**

**Anesthetise the palatine mucous membrane, 1 cm from the gingival margin.  
(Gently inject without making the membrane blanche, 1/4 of the cartridge will suffice.)**

**Dental nerve block: inject into the vestibular sulcus and anesthetise along the nerve root as far as the bone, then inject 3/4 of the cartridge after aspirating for blood with the syringe at 30° to the axis of the tooth.**

**After several minutes, ensure good anesthesia: no sensation in the mucous membrane and the patient describes a "dead" feeling on percussion of the tooth.**



**Figure 74**  
**DENTAL ANESTHESIA**  
**FIGURE**

## **Mandible**

**It is necessary to know the innervation of the inferior dental nerve:**

**A local/regional anesthetic or nerve block of the inferior dental nerve at the level**

**of its entrance into the dental canal at the spine of Spix, in sight of the internal branch which climbs above the mandible.**

**Classical technique: with the patient's mouth wide open, the edge of the left index finger is placed on the lower molars, with the tip of the finger palpating the border of the ascending branch of the nerve. The needle is introduced 10 to 15 mm behind the point of the index finger, then advanced 10 to 15 mm along the nerve, the body of the syringe situated at the level of the canines or the opposite pre-molars. After aspirating, slowly inject 3/4 of the cartridge into the entrance of the dental canal.**

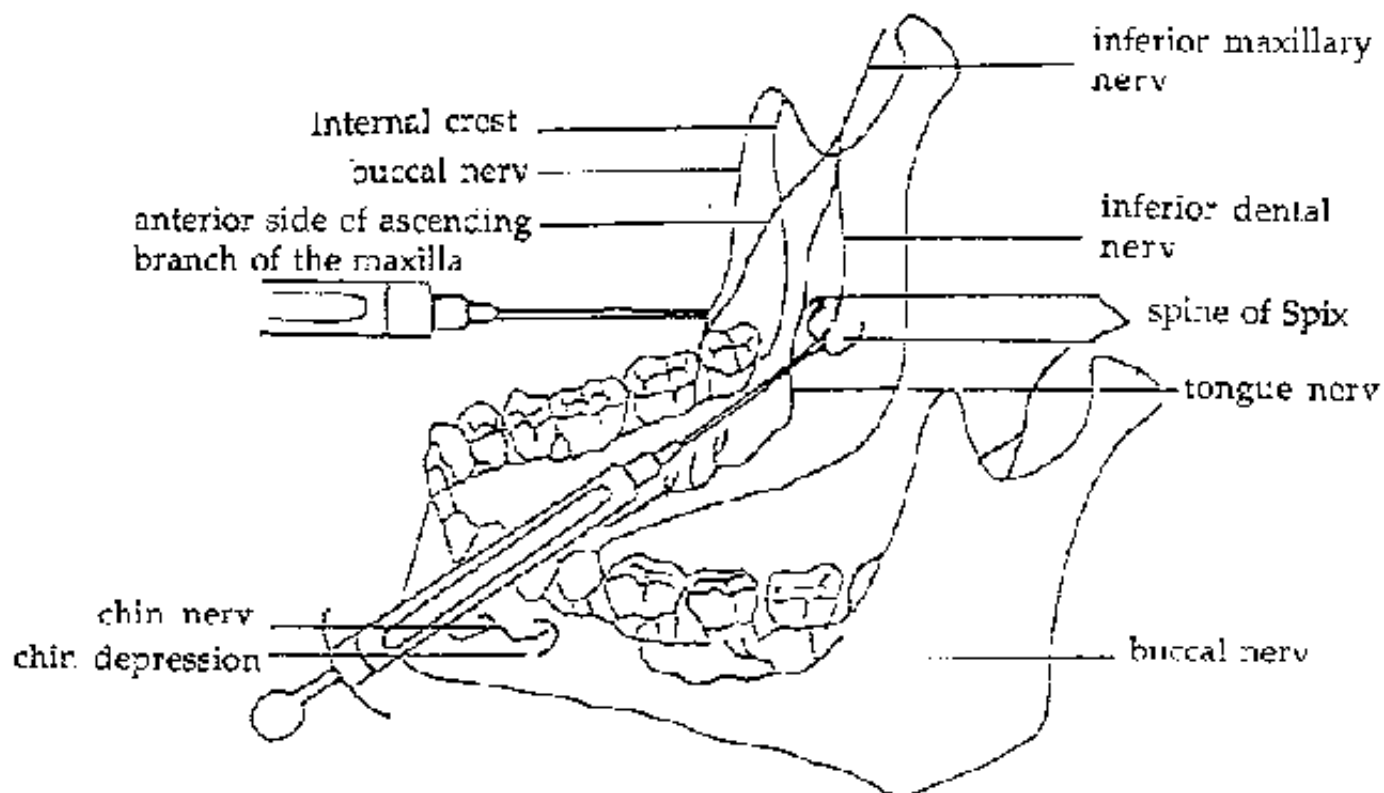
**Variation: with the patient's mouth wide open, use the left thumb to palpate the junction of the ascending anterior branch and the horizontal branch of the dental nerve. The index finger is placed on the external auditory canal and the other finger on the posterior angle of the mandible. These 3 fingers delineate the summit of the triangle. The body of the syringe rests on the canines or opposite pre-molars, advance the needle along the nerve root in the direction of the bisection of the angle of the triangle, which represents the geometric line of the entrance of the dental canal. After aspirating, inject 3/4 of the cartridge. In children, the entrance of the dental canal is lower, the body of the syringe will be in contact with the canines or the opposite upper pre-molars.**

**To extract a molar, always anaesthetise the buccal nerve. Advance the needle obliquely and behind into the entrance of the vestibular sulcus, opposite the second or third molar, until bone is reached, and inject 1/4 of the cartridge.**

**In cases with persistent sensation of the lingual innervation of the gum,**

**anesthetise the lingual nerve, as for palatine anesthesia.**

**For movable and decaying teeth, limit local anesthesia (vestibular and lingular) as for the maxilla. It can be completed with an intraligamentary anesthetic. Advance a short needle vertically to the vestibular side, between the root of the tooth and the alveolar bone, then slowly inject 1/5 of the cartridge.**



**Figure 75**  
**ANESTHESIA OF THE LINGUAL NERVE**



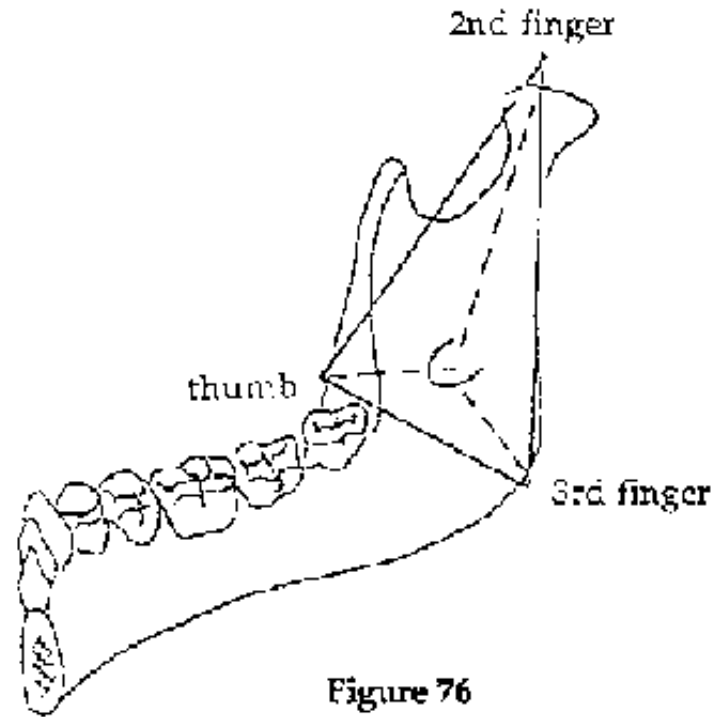
**FIGURE**

Figure 76  
*THE TRIANGLE*

**FIGURE****Extraction****Consists of:**

**2 steps: one dental, the other alveolar**

**3 movements to remove the tooth:**

- **syndesmotomy**
- **elevation or luxation**

## - avulsion

### Dental step

**Syndesmotomy Consists of separating the attached epithelium and the alveolar-dental ligaments by inserting the point of the syndesmotome hook between the tooth and the gum, and then the alveolar bone. The syndesmotome should be held like a pen and supported on the adjoining teeth to prevent slippage.**

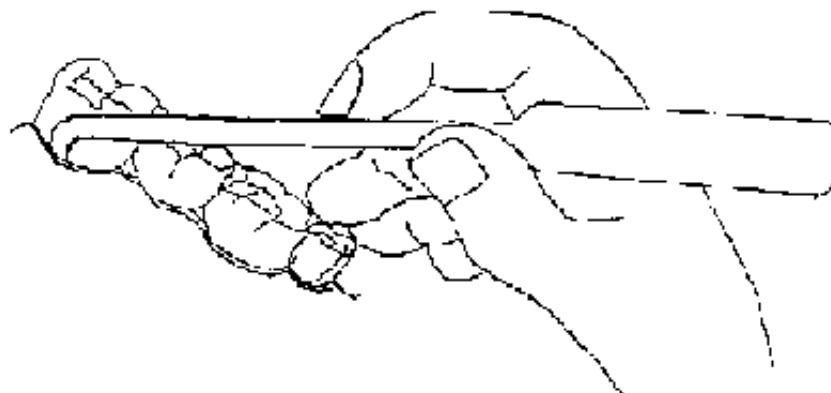


Figure 77

### FIGURE

### Elevation or dislocation of the tooth

**The elevators are levers which act to mobilise and dislocate the tooth from its socket. This is a critical part of the extraction. The teeth should not be forced or juggled because this can produce a fracture of the tooth or bone. A single elevation procedure, properly followed, will produce an effective extraction in 70 to 90 percent of extractions and is a unique and practical way of extracting a tooth with its roots.**

## - Instruments:

### Use:

- a bayonet elevator for the upper teeth.
- a right and left elevator for the lower teeth and the upper molars.




Figure 78  
ELEVATORS  
**FIGURE**

### - Technique:

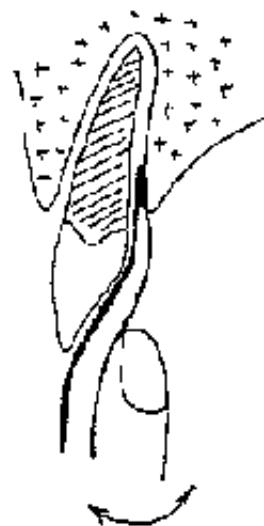
**With the assistance of a gauze compress, the fingers of the left hand surround the tooth for extraction, serving as a guard in case of slippage of the instrument.**

**The surface of the thin plate should always be in contact with the tooth, the elevators are inserted in the alveolar-dental space by gentle lateral movements. Then the tooth is mobilised by rotation and eventually (especially for the molars) by see-saw movements towards the vestibule (exterior) without pushing on the adjoining tooth.**

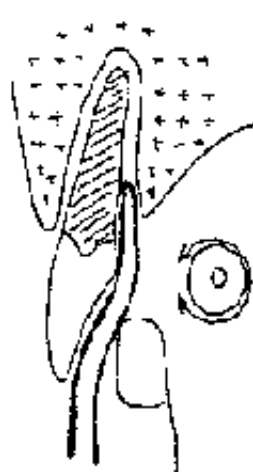
**The external bone (vestibular) at the level of the superior maxilla is particularly fragile, especially at the level of the anterior teeth. Work on the palatine side and opposite the tooth.**

**At the level of the mandible it is the internal bone (lingual) which is particularly fragile and contains the lingual nerve. Use the elevators on the vestibular side and on the side of the teeth (proximal side)**

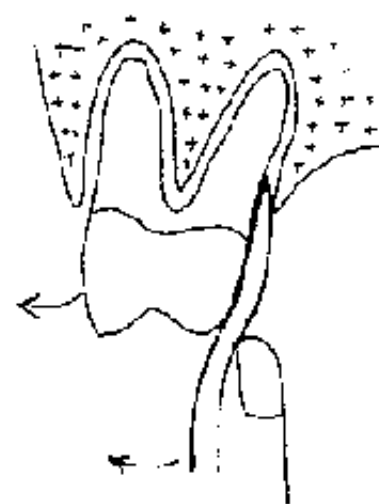
**A characteristic sign of good mobilisation is the "suction" noise which occurs when air enters between the tooth and the tooth socket.**



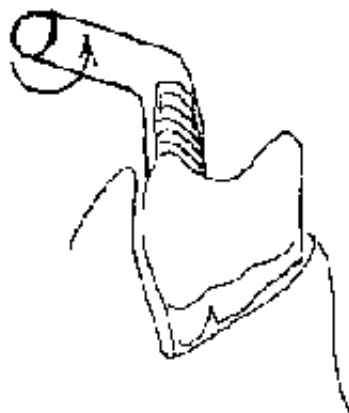
**Figure 80**  
LATERAL RETRACTION



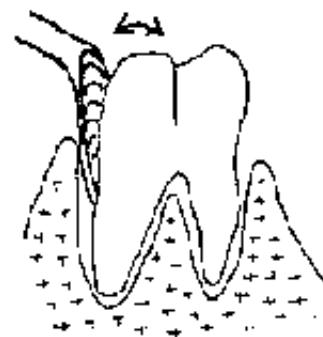
**Figure 81**  
ROTATION



**Figure 82**  
VESTIBULAR SEE SAW MOVEMENT



**Figure 83**  
ANTICLOCKWISE ROTATION

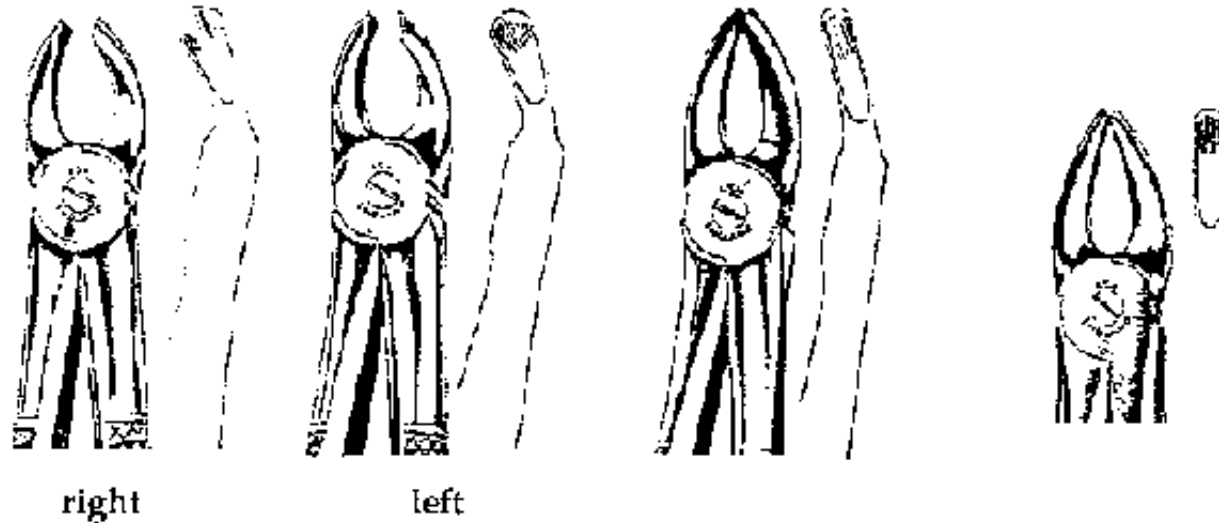


**Figure 84**  
ANTERO-POSTERIOR AND  
VESTIBULAR SEE SAW MOVEMENTS

**FIGURE**

**Avulsion or removal with dental forceps** If the steps have been followed, removal is often a simple "plucking out" of the tooth. The only exception is with the molars which often have wide roots limiting elevation and dislocation.

**- Instruments: dental forceps**



**Figure 85a**  
Molars

**Figure 85b**  
Pre-molars  
and roots

**Figure 85c**  
Canines and incisors

**Figures 85 : DENTAL FORCEPS FOR THE MAXILLA**

## **FIGURE**




Figure 86a  
Molars

Figure 86b  
Incisors, canines, roots  
and pre-molars

**Figures 86 : DENTAL FORCEPS FOR THE MANDIBLE**

The dental forceps for the upper roots serves also for the lower roots

**FIGURE**

**- Technique:**

**The index finger should be placed between the two handles of the dental forceps to abut in case of slippage and sudden closure of the prongs of the instrument. The movement is one of traction in the axial plane of the tooth.**

**In the case of molars in which simple luxation will not be possible, it is necessary to "work" at the tooth with the appropriate davier before trying to remove it. Use see-saw and rotatory movements, without forcing the tooth in order to avoid fracturing the roots or the bone.**

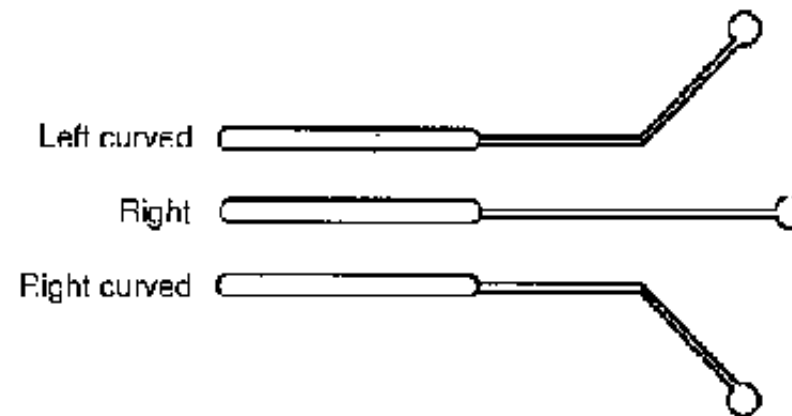
**The extracted tooth should be examined to ensure that the roots have not been**

**fractured.**

## **Alveolar step**

**Once a tooth has been extracted, carry out a systematic review of the tooth socket.**

- **Examine the border of the mucus membrane: ensure that it has not been torn by the different instruments, and does not require suturing.**
- **Examine the alveolar bone and the tooth socket, looking for a fracture which may require ablation of a sequestrum, to avoid pain, infection and scar formation.**
- **Examine the base of the tooth socket and curette to remove the debris, granulation tissue, and especially a granuloma or cyst, and also to prevent the risk of hemorrhage, infection and the formation of scar tissue.**



**Figure 87**  
**CURETTES**



## FIGURE

- **Compress the borders of the socket between the thumb and index finger and ask the patient to bite hard on 1 or 2 compresses for 30 minutes to produce hemostasis and coagulation.**
- **Prescribe mouth washes for 24 hours to check for hemorrhages.**
- **Recommend a semi-liquid diet for the first day.**

### Complications

#### Hemorrhage

**In most cases this is due to poor inspection and debridement of the tooth socket (leaving a granuloma or a cyst in place). after local anesthetic, clean the socket with a curette, then bite on a compress.**

#### Alveolitis

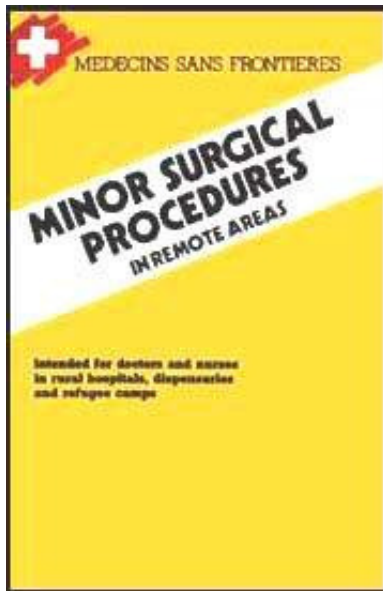
**Due to anoxia of the bone or an alveolar sequestration left in place, producing severe lancing pain 2 to 3 days after the intervention. Clean the socket, then introduce a wick with gentian violet end leave for at least 3 or 4 days. Prescribe analgesics and antibiotics in case of infection.**

#### Infection

**May exist before but usually occurs after extraction, due to an error in aseptic**

**technique, sequestered bone, a residual nerve root or a non curetted cyst. Inspect and clean the socket under local anesthetic and prescribe an antibiotic for 6 to 8 days, with or without an anti-inflammatory (ampicillin: 2 g/day for an adult).**

[Home](#) > [ar](#).[cn](#).[de](#).[en](#).[es](#).[fr](#).[id](#).[it](#).[ph](#).[po](#).[ru](#).[sw](#)



 **Minor Surgical Procedures in Remote Areas (MSF, 1989, 172 p.)**



**Chapter 5: uro-genital procedures**



**Urinary catheterisation**



**Reduction of a paraphimosis**



**Episiotomy**



**Suturing episiotomies or perineal tears**



**Intra-uterine procedures**



**Treatment of a bartholin abscess**

**Minor Surgical Procedures in Remote Areas (MSF, 1989, 172 p.)**

**Chapter 5: uro-genital procedures**

**Urinary catheterisation**

**Drainage of urine**

## **Indication**

### **Acute retention of urine**

#### **Urgent procedure is necessary for:**

- **Narrowing of the urethra**
- **Adenoma or cancer of the prostate**
- **Pelvic tumor**
- **Pelvis trauma**
- **Paraplegia**

### **Urethral catheterisation**

**(for men)**

#### **Material**


- **Sterilised gloves and drapes**
- **Sterile catheters, generally Foleys n° 12,14,18 for example**
- **Lubrication with chlorhexidine (+ cetrimide) (see table page 7)**
- **Sterile compresses**
- **10 ml syringe**

#### **Technique**

**(Figures 88, 89)**

- **Careful disinfection of the meatus, the glan and the prepuce, through the hole in the drapes.**
- **Coat the catheter with chlorhexidine (+ cetrimide) (see table page 7)**
- **The left hand holds the penis vertically**
- **The right hand carefully introduces the catheter through the meatus.**
- **Change the size of the catheter if introduction is difficult.**
- **When the catheter reaches the bulbar angle (13 to 15 cm), direct it towards the base.**
- **NEVER FORCE THE CATHETER, it is better to use a suprapubic catheter than to traumatise the urethra.**
- **Advance the catheter to the hilt before inflating the balloon (5 to 10 ml of liquid).**
- **Next, gently pull the catheter until the balloon abuts on the bladder neck.**
- **Always replace the prepuce around the glans, to prevent a paraphymosis.**
- **If the catheter is to remain in place, connect it to a sterile urine container, otherwise to a perfusion tube attached to a short necked bottle.**
- **Clean the meatus each day, and eventually, depending on the clinical context,**


**institute antibiotic treatment (cotrimoxazole: 1,600 mg de SMX/day in 2 divided doses x 5 days for an adult.**



**Figure 88**

**MALE CATHETERISATION : ensure a rigorous aseptic technique**

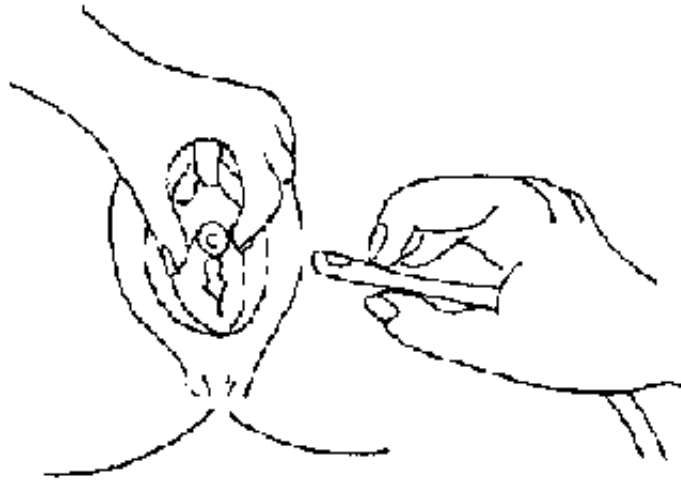
**FIGURE**



**Figure 89**

*MALE CATHETERISATION: advance the catheter to the hill*

**FIGURE**



**Figure 90**

**FEMALE CATHETERISATION:** separate the lips with the left hand to uncover the meatus, and clean with a solution of chlorhexidine cetrimide, always cleaning towards the anus. Follow the same insertion technique as in males.

## **FIGURE**

### **Suprapubic catheterisation**

#### **Indications**

**When urethral catheterisation presents difficulties, and when there is a risk of damage to the urethra with the catheter (trauma to the bladder, trauma to the urethra, and urethral stenosis, etc.).**

**The bladder must be dilated: A DISTENDED BLADDER IS OBLIGATORY.**

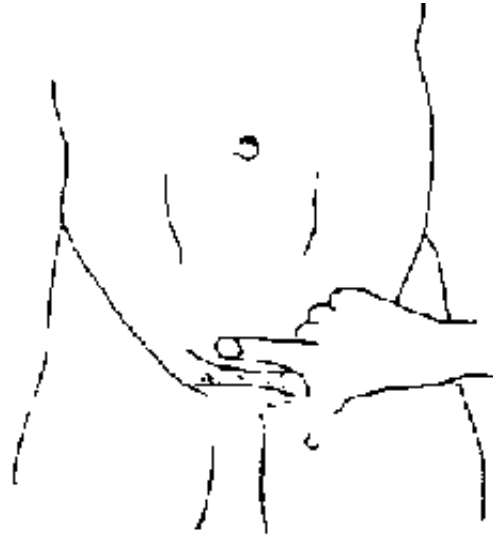#### **Material**

- **A prepared pack exists with a unique "cystocath". If not available, a large trochar and long catheter perforated at one end (at least 14G), can be used.**
- **Drapes with a hole, and sterile gloves**
- **Suture material**
- **Local anesthetic**

## **Technique**

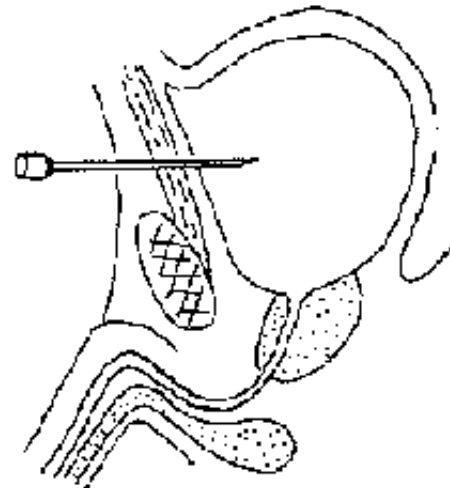
- **Shave and then disinfect the suprapubic region with polyvidone iodine (see table page 7).**
- **Make a bubble in the skin with lidocaine a finger breadth above the symphysis pubis in the median line. Anesthetise the deep tissue planes (Figure 91).**
- **With the same syringe ensure that aspiration produces urine.**
- **Puncture through the anesthetised bubble, asking the patient to cough.**
- **Introduce the perforated drain: advance 10 to 15 cm of the catheter, remove the trocar and attach the catheter to a sterile urine container.**
- **Fix the drain to the skin with a non resorbable suture and a dressing.**
- **Clean the drain at least once a day and institute urinary antibiotic treatment (cotrimoxazo/e: 1,600 mg of SMX/day in 2 doses for adults x 5 days) (Figures 92, 93, 94).**





**Figure 91**  
**CONFIRMING A DISTENDED BLADDER :** puncture a finger breadth above the symphysis

**FIGURE**



**Figure 92**  
**SUPRAPUBIC CATHETERISATION :** position of the trocar

# FIGURE

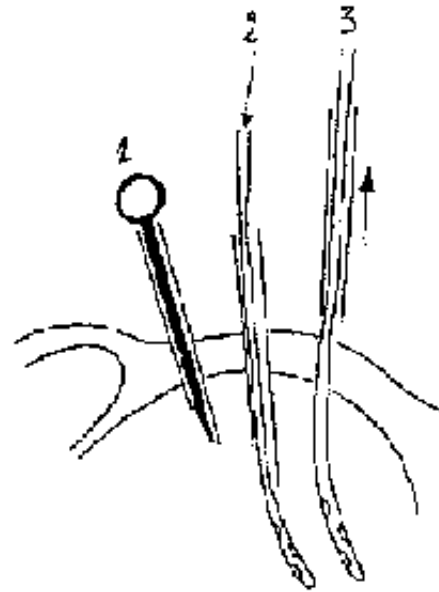
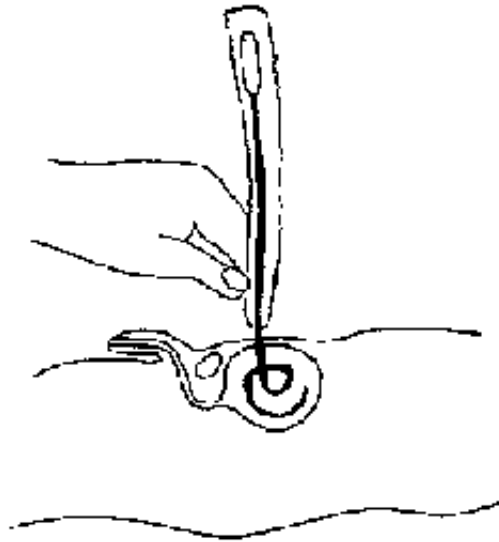


figure 93  
STAGES OF SUPRAPUBIC CATHETERISATION

# FIGURE



**Figure 94**  
14 G STERILE CATHETER advanced 10 to 15 cm, fixed on the skin  
and cleaned each day

## FIGURE

### Reduction of a paraphimosis

**Acute swelling of the retracted prepuce.**

**Urgent treatment is required to prevent glans necrosis**

### Technique

### Children

- **It is almost always possible to reduce manually, without anesthesia, depending**

**on the condition of the patient. Light sedation with diazepam is sometimes necessary.**

- **Compress the glans with the fingers of the left hand, while holding the shaft of the penis with the other hand.**
- **Daily baths with a solution of chlorhexidine (+ cetrimide) (See table page 7).**

### **Adult**

- **Often, manual reduction is difficult or impossible.**
- **Place an incision in the axis of the penis on the dorsal surface (the urethra is situated on the ventral surface).**
- **Incise the two rolls of prepuccial skin as far as the deep ligament which is constricting the penis.**
- **The reduction will then be easy.**
- **A circumcision is recommended a few weeks later.**



Figure 95  
Manual reduction  
in a child

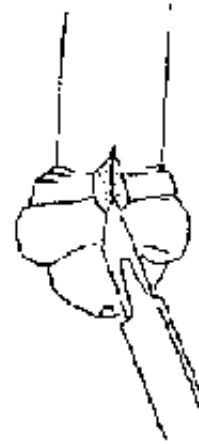


Figure 96  
Dorsal incision with a scalpel  
in adults

## FIGURE

### Episiotomy

**Dissection of the perineum to enlarge the birth canal and to prevent a tear.**

### Indications

- **Pushing for more than 30 minutes increases pain and suffering.**
- **Occipito-posterior, face or forehead presentation.**
- **All obstetric maneuver, forceps, ventouse and symphysectomy.**
- **Perineal anomalies, retractile scars from previous deliveries.**

**In general, it is preferable to repair an episiotomy rather than to suture a perineal tear.**

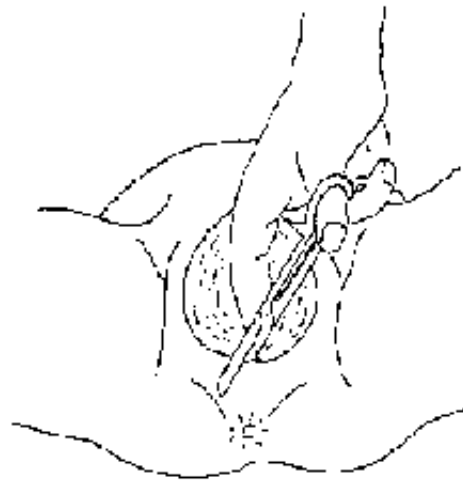
**The decision to do an episiotomy comes with experience.**

## **Material**

**Pair of sterile scissors (for example, Dauphin scissors or 16 cm pointed scissors).**

## **Technique**

**After disinfection of the skin with chlorhexidine (+ cetrimide) (see table page 7), place the scissors between the presenting part and a line postero-lateral to the vulva, with the next contraction cut obliquely and posteriorly for approximately 4 cm.**



**Figure 97 : EPISIOTOMY**  
Postero-lateral incision of 4 cm, protecting the head with the other hand.

## **FIGURE**

### **Suturing episiotomies or perineal tears**

**A tear is complete when it reaches the anal sphincter and is complicated when it reaches the rectal mucosa.**

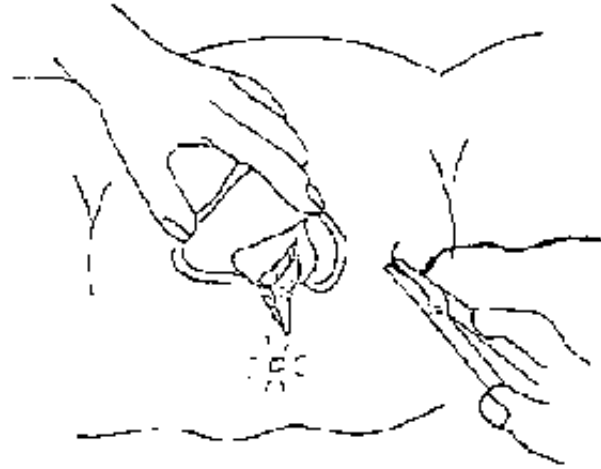
**NB: Suture an episiotomy after delivery.**

#### **Material**

- **Sterile "abscess-suture" box containing scissors, toothed dissecting forceps, needle holders and needles.**
- **Resorbable and non resorbable suture material.**
- **Sterile drapes and gloves.**
- **Make a sterile tampon: gauze tied with a large suture and then placed in the vagina to collect uterine secretions.**

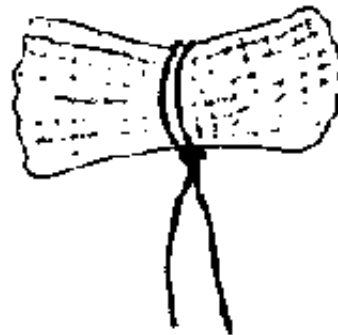
#### **Technique**

- **Local anesthesia with lidocaine 1% in the tissue layers except for the rectal mucosa, at least 5 ml especially under the skin.**
- **After cleaning the perineum and vagina with polyvidone iodine, place the sterile drapes under the buttocks, on the abdomen and on the thighs (see table 1).**



**Figure 98**  
**SUTURING A PERINEAL TEAR**  
Expose well with the left hand

**FIGURE**



**Figure 99**  
**TAMPON : gauze compress with**  
**ligature**

**FIGURE**



## **1st: episiotomy or simple perineal tear**

### **Figure 100**

**Repair the muco-cutaneous junction and pass the first suture without producing a knot, to produce a good join of the layers.**

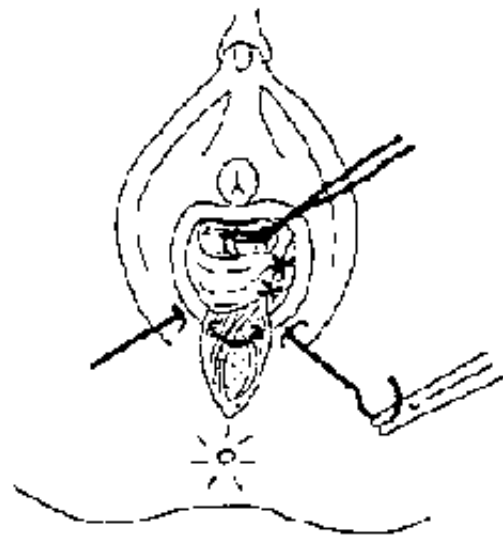
**Suture the mucosa of the vagina from inside outwards with resorbable sutures, sufficiently close and sufficiently deep to allow the passage of lochia during the following days, but not too deep as to prevent evacuation of the rectum.**

### **Figure 101**

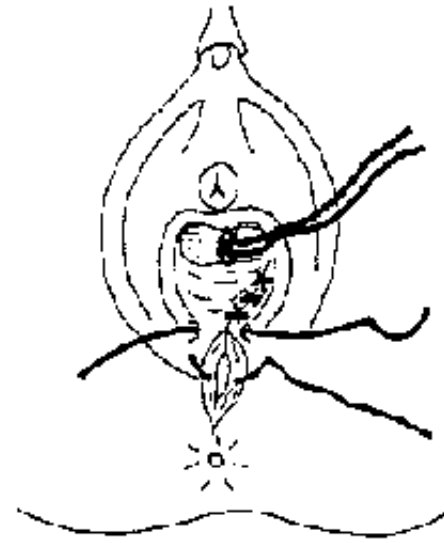
**Next, suture the muscle layer with 2 or 3 resorbable sutures, if possible.**

### **Figure 102**

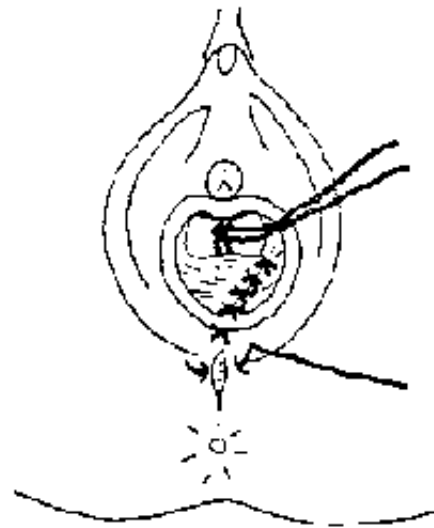
**Close the skin ensuring that the sutures are not too close together, if possible use the Blair-Donati method. Begin at a point situated at the apex of the wound and which does not already contain a suture, and control the procedure with a finger placed in the rectum.**



**Figure 100**  
*SIMPLE PERINEAL TEAR : SUTURE OF THE MUCOSA*



**Figure 101**  
*SUTURE OF THE MUSCLE*



**Figure 102 : SUTURE OF THE SKIN**

**FIGURE**

## 2nd: complete perineal tear

### Figures 103, 104

Rupture of the anal sphincter, a tear of the muscle fibres, easily identify by touching the anal region.

Suture the sphincter with slowly resorbable sutures, with 2 or 3 X-points. Then proceed as before. Control the procedure with a finger placed in the rectum.



Figure 103  
COMPLETE PERINEAL TEAR  
Suture of the sphincter ..

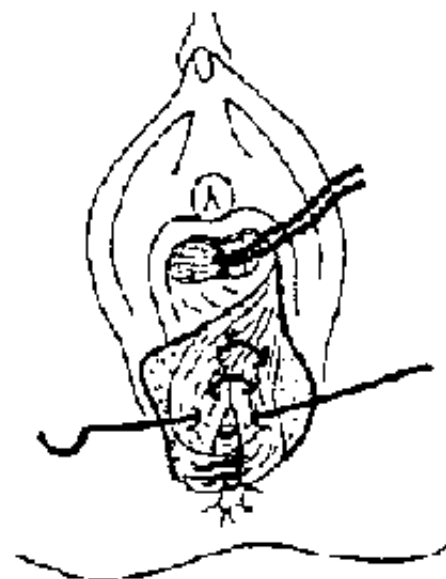


Figure 104  
...then of the muscle

## FIGURE

## 3rd: complicated perineal tear

## Figure 105

**Protect from the stool with a rectal tampon (similar to the vaginal tampon) and clean with polyvidone iodine (see table page 7).**

**Suture the rectal mucosa with separate resorbable sutures from the inside outwards, tying the knots on the rectal surface. Then proceed as before. Control the procedure with a finger placed in the rectum.**

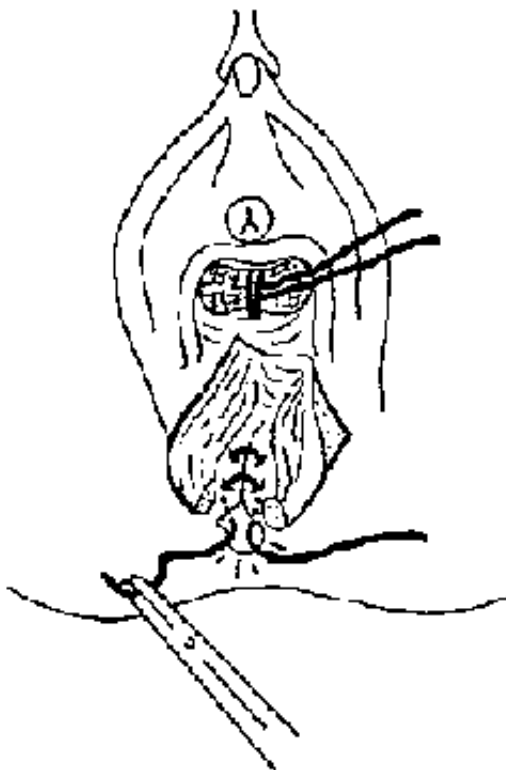


Figure 105  
COMPLICATED PERINEAL TEAR : suture of the rectal mucosa

## FIGURE

**In all cases, clean the vagina with a diluted solution of chlorhexidine (+ cetrimide) (see table page 7) and dry the wound as often as possible. Remove non resorbable sutures after 8 days.**

## **Complications**

**Breakdown of the suture.**

**In the case of an episiotomy, the scar may be long and unpleasant: encourage daily vaginal toilet.**

**In the case of a complete or complicated perineal tear, with anal incontinence, refer, if possible, to a surgeon.**

**Only prescribe antibiotics when the lochia are purulent, with associated intra-uterine procedures or if there is a post-partum fever.**

## **Intra-uterine procedures**

**General precautions (asepsis, antibiotic therapy, anesthesia, preventing trauma)**

**OBLIGATORY ASEPSTS (clean with chlorhexidine (+ cetrimide) (see table page 7), drapes, gloves, and sterile compresses etc.), ALL INTRAUTERTNE PROCEDURES MUST BE FOLLOWED BY ANTIBIOTIC THERAPY, (PPF 4 million units for example IM for at least 5 days or ampieillin), HEMOSTASIS (ergometrine 0,1 mg IM x 1).**

**ALL INTRA-UTERINE PROCEDURES MUST BE CONDUCTED UNDER THE AUSPICES OF AN ANESTHETIST, the most rapid general anesthetic is ketamine IM (5**

**mg/kg).**

**ALL INTRA-UTERINE PROCEDURES MUST BE AS ATRAUMATIC AS POSSIBLE, for in all parts of the third world, sterility is seen not only as an individual problem but also a family and social problem.**

**All intra-uterine procedures, and in particular curettage, need practical training. The technique cannot be learn from a manual.**

**All intra-uterine procedures risk hemorrhage: always ensure a good venous line.**

**Artificial removal of the placenta**

**Manual removal of the placenta.**

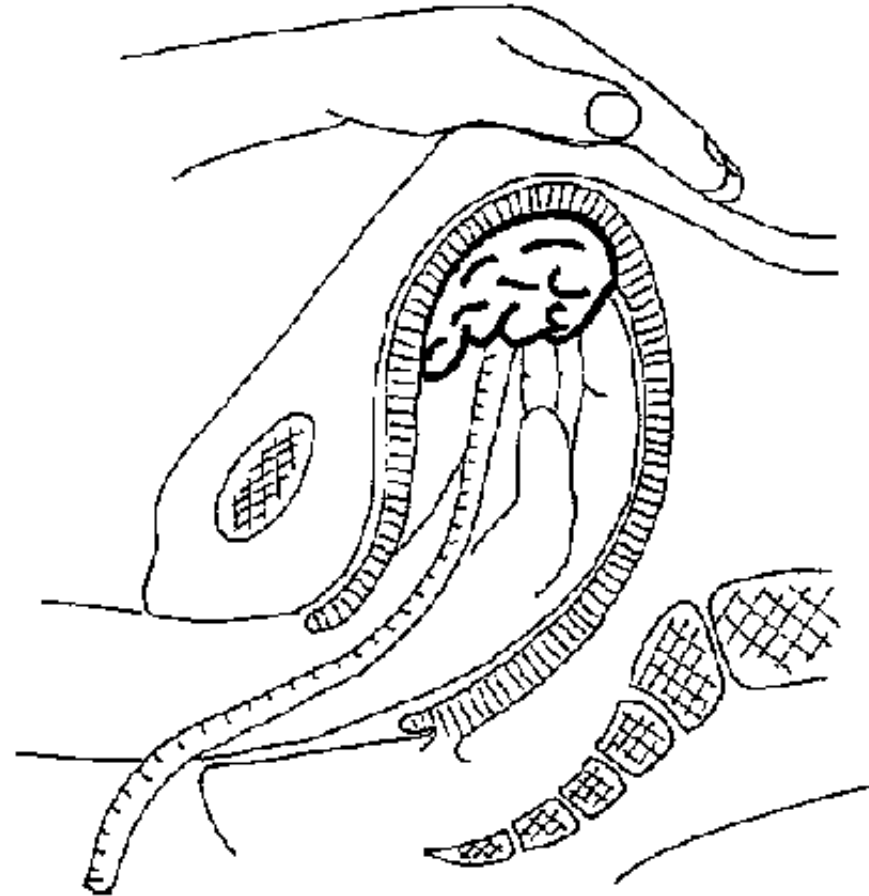
**Indication**

**When more than 45 minutes elapses between a normal delivery and the delivery of the placenta.**

**Technique  
(Figure 106)**

- **Intravenous line.**
- **Patient in lithotomy position, general anesthetic, clean the vagina with antiseptic, and wear sterile gloves.**
- **The left hand of the surgeon grasps the fundus of the uterus.**

- **The right hand pronated is advanced to the fundus and the fingers find the line of cleavage between the placenta and the uterine wall, that is to say the hand is advanced until the forearm is within the genital canal.**
- **Once the line of cleavage has been found, use the edge of the pronated hand as a knife, to dislodge the placenta.**
- **Next, explore with the fingers to ensure that the uterine cavity is empty and remove the placenta before the uterus contract.**
- **Give systemic antibiotics for at least 5 days.**
- **1 injection of ergometrine 0,1 mg IM.**



**Figure 106**

**ARTIFICIAL REMOVAL OF THE PLACENTA**

Left hand on the fundus, fingers of the right hand inserted between the placenta and uterine wall, removal with the cubital border of the hand

**FIGURE**

**Uterine exploration**



## **Exploration of the uterus with a finger.**

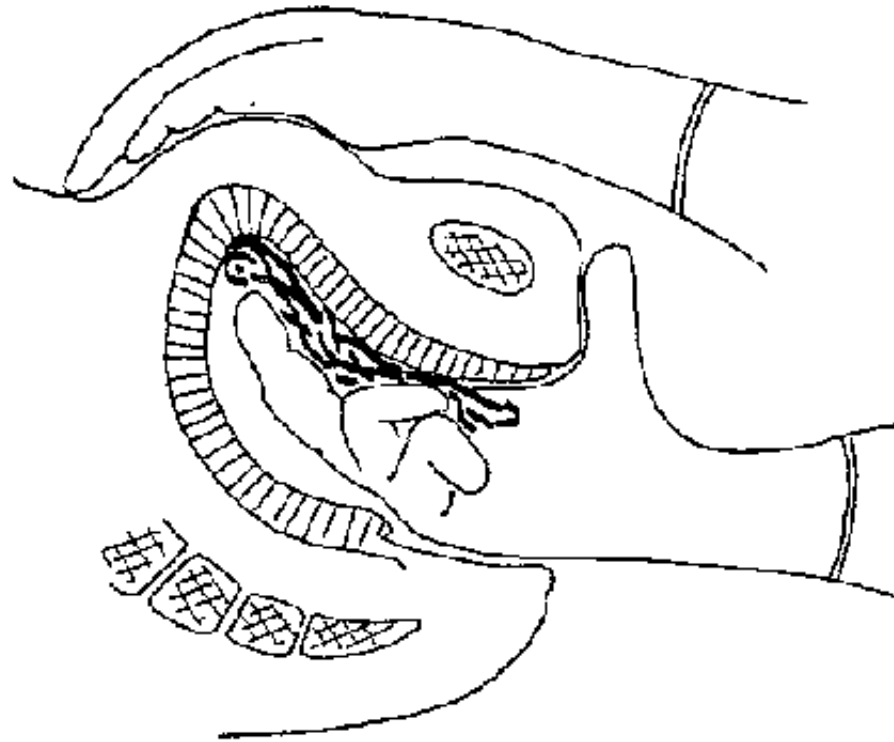
### **Indications**

- **Any suspicion of a retained placenta (always examine a placenta).**
- **Hemorrhage following delivery: all hemorrhages occurring within 24 hours of delivery.**

**Attention: if the placenta is complete and the uterus is contracted, only examine under a general anesthetic.**

### **Technique**

- **Intravenous catheter**
- **The same procedure and aseptic technique as for artificial removal of the placenta.**
- **Systematically explore the uterus: the two faces, the two sides, the fundus and the two corners with the finger searching for and removing placental tissue.**
- **Systemic antibiotic therapy for at least 5 days.**



**Figure 107**

**DIGITAL CURETTAGE**

Systematic exploration with finger of the sides, walls, fundus and corners of the uterus

**FIGURE**

- **Ergometrine 0,1 mg IM digital curettage**

**Digital extraction of placental fragments after a miscarriage.**

## **Indications**

- **Hemorrhage or retention of products of conception.**
- **Dilate the cervix with one, or two fingers if possible.**

## **Technique (Figure 107)**

- **Same preparation and asepsis as for uterine exploration.**
- **Introduce the index and middle fingers into the uterine cavity if possible.**
- **Examine systematically and remove residual fragments.**
- **Antibiotic therapy for at least 5 days.**

## **Curettage**

**Removal of the remaining products of conception following a miscarriage.**

## **Indications**

**When dilatation of the cervical neck is insufficient using curette technique: always prefer digital curettage when possible.**

**ATTENTION: curettage of a febrile patient: treat with antibiotics and wait for a fall in fever before curetting. The decision must be weighed against the risk of hemorrhage.**

## **Material**

- **Speculum or vagina valve, Muzeux forceps (or Pozzi to hold the cervix, bougies for dilating the neck).**
- **Blunt curette, without hole, not too small: if too small, there is a risk of trauma. With a large curette, it is less dangerous, the diameter should be approximately the size of a tea-spoon and the limit is the degree of dilatation of the neck obtained with the bougies.**

## **Technique (Figure 108)**

- **Place the patient in lithotomy, position the sterile drapes, clean the perineum and vagina with polyvidone iodine (see table page 7), give general anesthesia.**
- **Introduce a speculum or vagina valve, holding the cervix with certical forceps (Museux forceps).**
- **Introduce the first dilator into the cervical canal, gently in the axis of the uterus ; there is a sudden loss of resistance when the internal os is reached. This first dilator is pushed as far as the fundus in order to estimate the size. With the following dilators, introduce by increasing sizes, until the cervix is dilated sufficiently to introduce the curette. ATTENTION: do not force: there is a risk of uterine perforation !**
- **The curette is then introduces as far as the fundus and explored, with the products drawn towards the cervical neck.**

- **The curette should be held between the thumb and index finger, with the other fingers on the shaft, allowing forward and backward movement: do not place the curette in the palm of the hand.**
- **Remove the fragments and do not damage the mucosa. Do not wait for the grating sensation, which means that the curette is too deep.**
- **Systematically explore the sides, walls, fundus and corners and check with the finger that the uterus is empty.**
- **Systemic antibiotics for at least 5 days.**

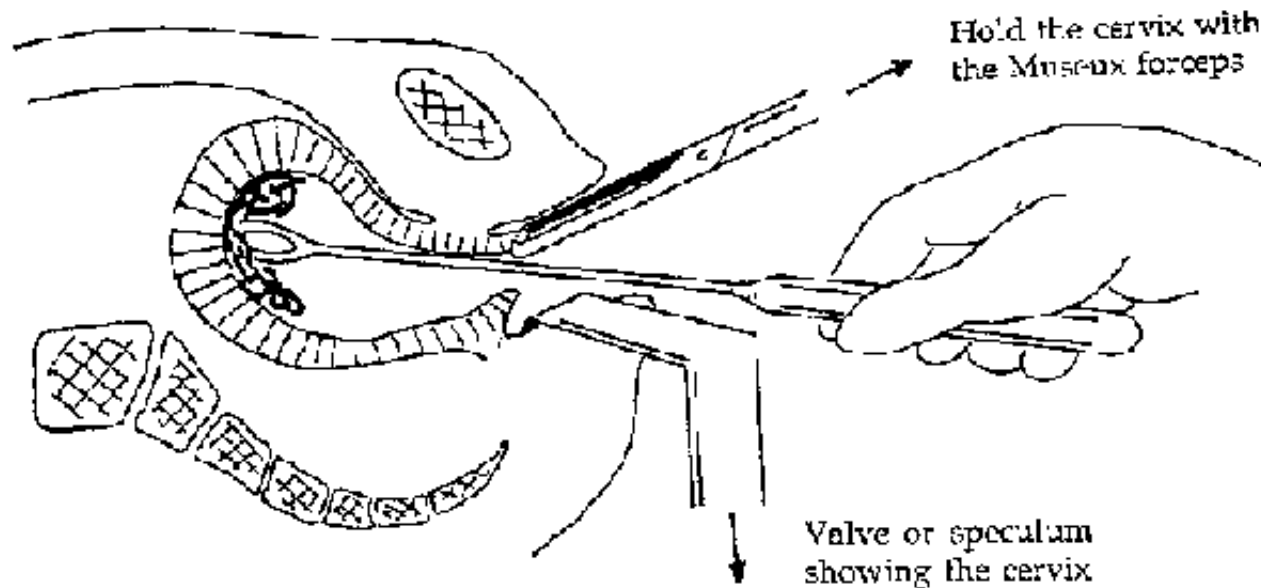


Figure 108

**FIGURE**

## **Complications (Figures 109, 110)**

- **Persistent hemorrhage: Incomplete curettage, followed by uterine inertia; administer 0,2 mg of ergometrine IM and repeat as needed up to 4 hours. Do not administer more than 1,5 mg.**
- **Cervical damage by dilatation: Usually partial, lateral or submucosal. Heals by itself.**
- **Perforation: When this is diagnosed (forced instrumentation producing severe pain), lying the patient down and administering antibiotics (ampicillin: 4 g/day in 4 divided doses for at least 7 days) is usually sufficient. Sometimes, signs of peritonitis appear in the following days (pain, contracture) and surgery is needed.**
- **Infections: Endometritis, salpingitis, pelviperitonitis, septicemia must be prevented by rigorous asepsis, atraumatic procedures and systemic antibiotic therapy.**
- **Sterility: Obstruction of the ovarian tubes, infection, incompetent cervix. Uterine adhesions, obstetrical complications (placenta previa, adhesions), ectopic pregnancies.**

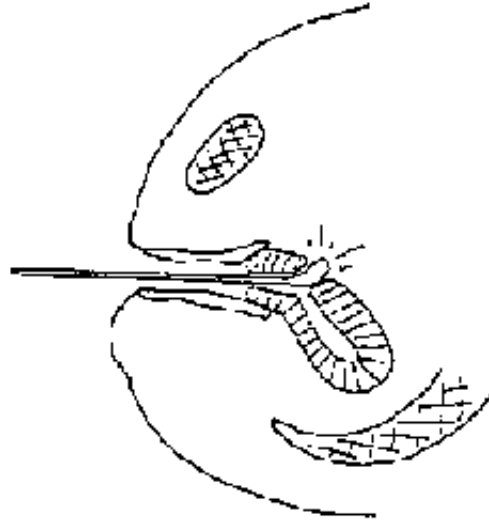


Figure 109  
Uterine perforation with a curette  
**FIGURE**




Figure 110  
Traumatic dilation  
Cervical rupture

**FIGURE**

**Treatment of a Bartholin abscess**

**Cyst or abscess of a Bartholin gland**

**Diagnostic**

**Inflammatory tumor, the size of a small egg, affecting the folds of the labia.**

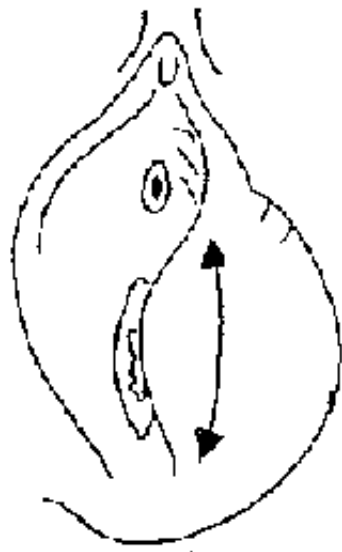
**Material**



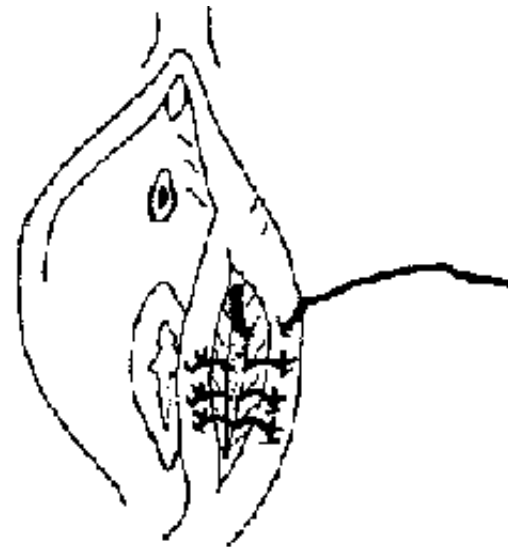
**Sterilised drapes and gloves, scalpel, dissecting forceps, scissors, needle holder, hooked needle, resorbable suture material, and sterile compresses.**

## Technique

- **A large vertical incision, at the muco-cutaneous junction, rather than on the inside of the labia.**
- **Clean with polyvidone iodine (see table page 7).**
- **Marsupialisation of the gland or cyst, that's to say, the walls of the gland is sutured to the skin, to keep it open and to prevent recurrence.**



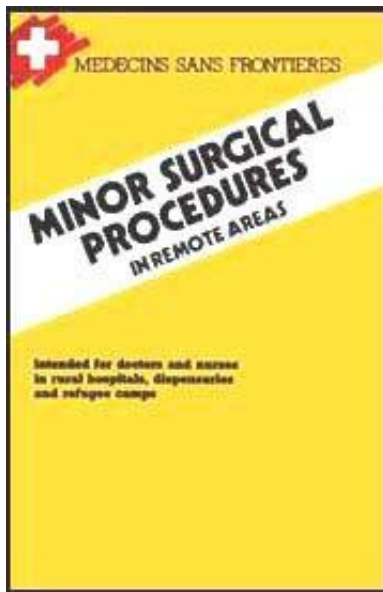
**Figure 111**  
Incision at the muco-cutaneous junction








**Figure 112**  
**MARSUPIALISATION:** diagram of the cyst and skin separated by the resorbable sutures.

**FIGURE**

[Home](#) > [ar](#).[cn](#).[de](#).[en](#).[es](#).[fr](#).[id](#).[it](#).[ph](#).[po](#).[ru](#).[sw](#)



 **Minor Surgical Procedures in Remote Areas (MSF, 1989, 172 p.)**

- ➔  **Chapter 6: treatment of trauma**
  -  **Fractures and dislocations: the basics**
  -  **Shoulder and arm trauma**
  -  **Trauma of the lower limb**
  -  **Period of immobilization for major fractures**

## **Minor Surgical Procedures in Remote Areas (MSF, 1989, 172 p.)**

### **Chapter 6: treatment of trauma**

#### **Fractures and dislocations: the basics**

**It is possible to treat major fractures and dislocations in isolated areas, without sophisticated surgery or radiography.**

**A service can be provided with the minimal material, producing a satisfactory**

## **reduction and total recuperation of the fracture.**

**It should be noted that in certain areas traditional fracture treatments exist (clay plasters, medicinal plants, bamboo lattices.) which sometimes produce good results but more frequently lead to catastrophic deformities and reduction of mobility. Be aware that immobilisation for a long period is sometimes unacceptable.**

### **Diagnosis of a fracture**

**This is often easy: pain, abnormal movement, abnormal position, bruising, deformity, reduced function. It is dangerous to look for a fracture by palpating; it causes pain, etc.**

**It is sometimes difficult but necessary to have an X-ray. If this is not possible (no evacuation possibilities, no hospital) and in doubtful cases, it is better to immobilise the fracture in a posterior plaster rather than in a full circular plaster. For example, in children when a forearm fracture is suspected, for which only an X-ray will confirm the diagnosis, a splint maintained with a bandage will produce good results, and with no risk.**

### **Looking for complications**

- Skin: Look for a wound or puncture. All wounds with fractures require dressings and antibiotics (penicillin or ampicillin).**
- Pulses: look carefully for peripheral pulses.**

- **Paralysis: explore the nerves.**
- **Multiple trauma: A fracture may hide other trauma, always give priority to hemorrhage, to cardiovascular problems, etc.**

**ATTENTION: In isolated areas, treatments are deliberately chosen for their simplicity, but obviously other methods exist. Moreover, certain fractures and dislocations have deliberately been omitted because they are rare or because they require sophisticated treatment which would not be available in an isolated dispensary in the third world.**

## **Constructing a plaster**

### **Material**

- **Plaster of Paris rolls of 2 to 3 metres length, 10,15 or 20 cm width. Application time: 2 to 5 minutes Drying time: 24 to 48 hours Stock in a dry place, maintain the airtight packing, and throw away damp rolls.**
- **Tubular stocking of different diameters**
- **Cotton**
- **Container with tepid water**
- **The construction of a plaster requires at least two people, to hold the limb, to reduce it and to maintain it in right position.**

## **Technique (Figures 113a to 113c)**

### **Fitting the tubular stocking**

**The diameter of the stocking must be chosen according to the type of fracture; it must not be too tight, it must not produce folds and it must cover the limb. It must be longer than the plaster at both ends. Rather than unrolling it before application, it is better to carefully unroll the stocking over the limb.**

### **Application of the cotton**

**1/2 cm thickness covering all bony projections and flexor skin folds.**

### **Immersion of the plaster rolls in water**

#### **Remove from the packing material**

**Take in both hands, the left hand holding the free end of the roll, and unfurl several centimeters.**

**The right hand holds the unrolled plaster.**

**Immerse the roll, thus maintained, with both hands.**

**Maintain the plaster in the water until all the air bubbles have disappeared.**

**Squeeze out the water, continuing to hold the free end of the plaster.**

## **Unrolling the plaster**

**Apply the plaster from the proximal end of the limb, ensuring that several centimeters of the stocking are showing.**

**The plaster is unrolled over the limb and must not be tightened, this helps to prevent ischemia.**

**The different rolls of plaster must overlap.**

**Four or five rolls are usually needed.**

**Smooth each plaster roll with the palm of the hand before applying the next roll.**

**The assistant continues to hold the plaster with the hollow of the hand and never with the fingers. The application must be perfect and must not produce dangerous plaster folds at the flexural creases which can cause severe constriction (just like a tourniquet).**

**Each end of the stocking should be folded back onto the plaster.**

**The plaster should continue to be held in position by the assistant until it is dry and hard.**

**The plaster may be reinforced in the flexural creases with a splint prepared in advance: usually 5 or 6 plaster rolls.**

## **Special precautions**

## **(Figures 114a to 114d)**

### **A PLASTER MUST IMMOBILISE ADJACENT JOINTS.**

**To prevent vascular/nerve compression, it is almost obligatory to split a circular plaster from top to bottom. The plaster can be split using a scalpel just before it is completely dry.**

**All plasters must be put under surveillance and therefore hospitalisation for at least 24 hours is necessary.**

**Never hesitate to open and make a new plaster if there is the slightest hint of compression or poor reduction.**


**Always make a window in the plaster at the level of the folds.**

**Always elevate the plaster during sleep or confinement to bed.**

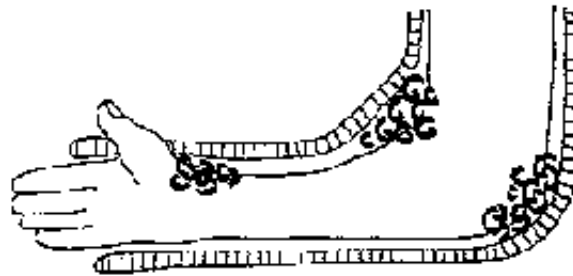
**Always write on the plaster the date it was applied and the time needed for the fracture to heal.**

**Do not hesitate to reconstruct a heavy plaster or reinforce a weak plaster. Always consider the constraints of living in a rural area.**

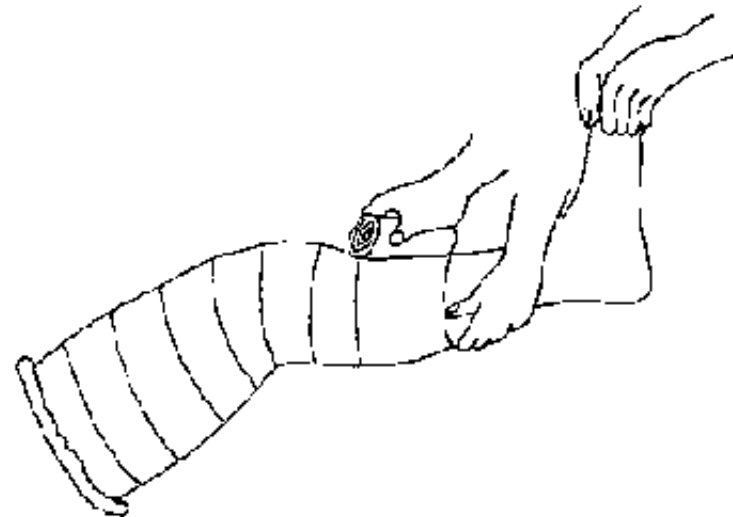




**Figure 113a**  
Immerse the plaster using both hands



**Figure 113b**  
Cotton on the bony protuberances and on the flexor folds



**Figure 113c**  
Roll the plaster bands along the limb ensuring that the turns overlap, while holding the plaster with the hollow of the hand

**Figures 113 : CONSTRUCTING A PLASTER**



# FIGURE

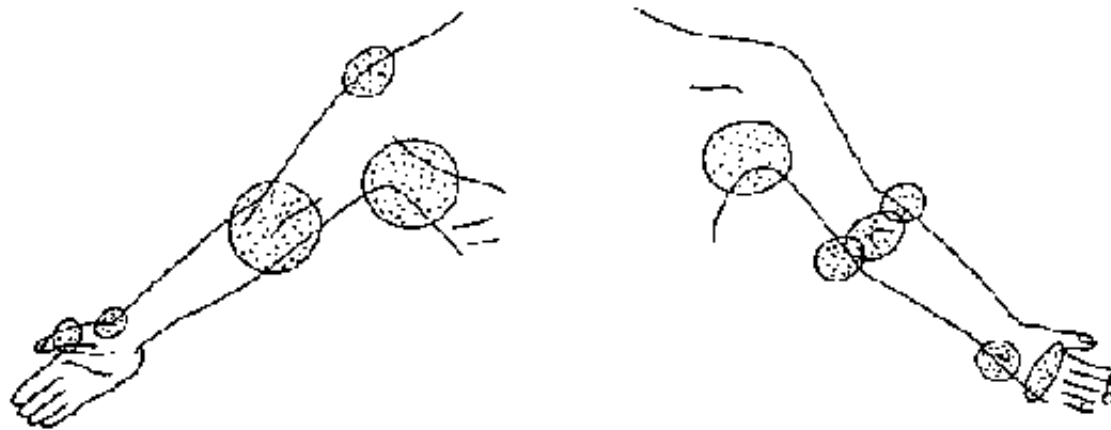


Figure 114a

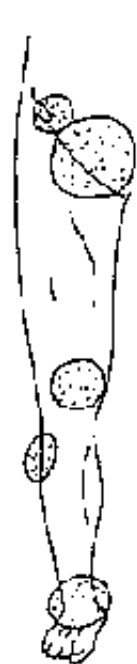


Figure 114b

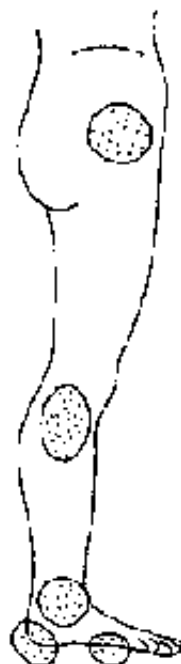


Figure 114c

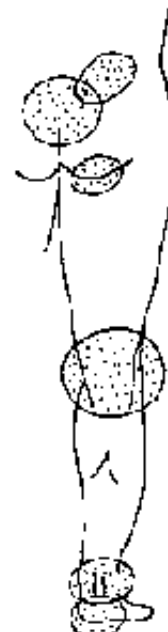
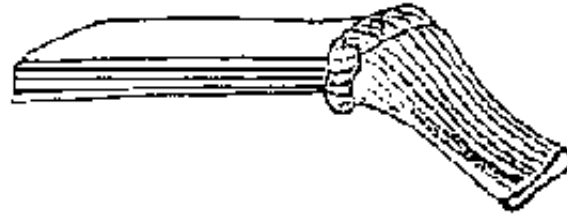


Figure 114d

**Figures 14 : DO NOT COMPRESS THE FOLLOWING AREAS**

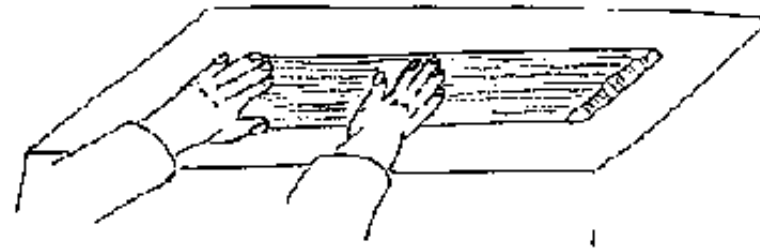
*Taken from "Techniques élémentaires pour médecins isolés"  
Les Agrégés du Pharo (Ref. bibliography)*

**FIGURE****Making a plaster splint****(Figures 115 to 119)****Prepare 12 to 15 thick plaster rolls the length of the limb to be immobilised.****Place the dry plaster rolls in a stocking of adequate length and width.****Immerse the stocking splint in tepid water until all the bubbles have disappeared (usually a little longer than the time required for a simple plaster roll), then spread out and flatten on a hard surface.****Apply the splint in the correct position on to the surface of the limb to be immobilised.****Wrap, without constricting, with non-elastic bandage.**



**Figure 115**  
Place the dry plaster rolls in a stocking

**FIGURE**



**Figure 116**  
Spread and flatten the plaster in the stocking

**FIGURE**

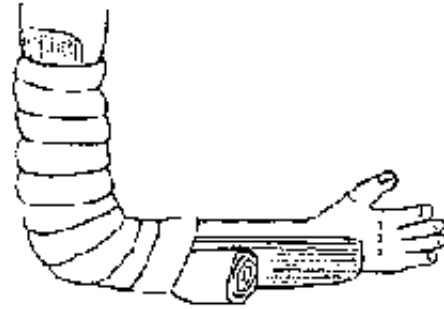


Figure 117  
Without constricting the limb, bandage around the splint

**FIGURE**

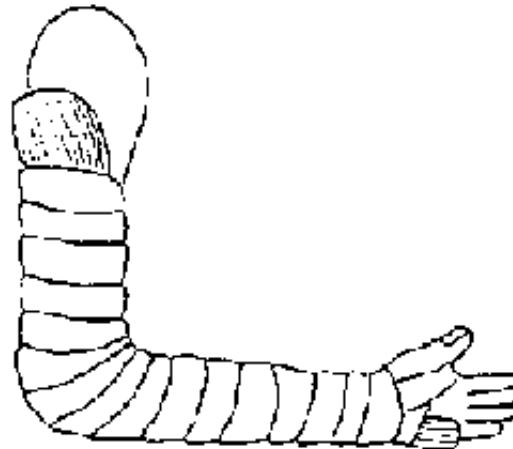


Figure 118  
Place cotton in the flexor creases and on the bony protuberances, immobilise the limb at 90°, thumb up, with wrist midway between pronation and supination

**FIGURE**



**Figure 119**

Make a window for the thumb in the end of the splint

## **FIGURE**

### **Instructions to follow for open fractures**

- **General anesthetic (ketamine) if the patient is fit.**
- **Treat the wound in the best possible aseptic conditions (operating theater, using sterile drapes and gloves etc.)**
- **Remove foreign bodies, excise bone splinters and necrotic tissue, and clean abundantly with chlorhexidine (+ cetrimide) (see table page 7).**
- **If the wound is recent and clean, attempt to close the skin.**
- **If skin tissue is lacking, cover the wound with sterile vaseline compresses and soak with polyvidone iodine (see table page 7).**
- **If possible, give anti-tetanus prophylaxis and systemic antibiotic therapy (procaine penicillin or PPF: 5 MUI/day for at least 5 days, or ampicillin: 3 or 4 g/day in an adult).**

- **Immobilise on a plaster splint (not a circular plaster to begin with)**
- **Apply regular dressings under strict aseptic conditions.**
- **As soon as the wound is healing, the splint can be changed for a circular plaster with a window cut over the wound to allow external care.**

## **Shoulder and arm trauma**

### **Fracture of the clavicle**

#### **Diagnosis**

**Pain, loss of shoulder movement and subcutaneous projections of the bony fragments.**

#### **Look for complications**

**Pulses, paralysis of nerves to the arm.**

#### **Treatment**

- **Reduction:**

**The operator stands behind the patient, who is seated on a stool, places his knee between the shoulder blades and pulls on the patient's shoulders.**

- **Maintenance:**

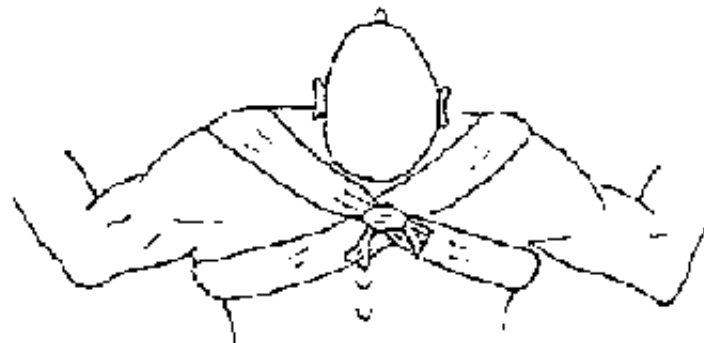
**Figure of 8 bandage. The best material to use is long tubular stocking filled with cotton. The bandage forms two rings which pass across the delto-pectoral**

**muscles and the armpit, and are tied in a knot on the back.**

**This bandage must be re-tied every 3 or 4 days and left in place for 3 weeks.**



**Figure 120**  
**REDUCTION**



**Figure 121**  
**MAINTAINED WITH A FIGURE OF 8 BANDAGE**

## **FIGURE**

### **Dislocation of the acromio-clavicular joint**

#### **Diagnosis**

**Often difficult without X-ray: exquisite pain at the level of the joint with mobility at the extremity of the clavicle.**

#### **Treatment**

**Reduce by pressing on the clavicle.**

**Immobilise by applying a sticky bandage (perforated adhesive tape), crossed and**

## **double thickness under the elbow.**



**Figure 122**  
*DOUBLE BANDIAGE*, perforated adhesive tape, pressing on the clavicle and passing under the elbow.

### **FIGURE**

## **Dislocation of the shoulder**

### **Diagnosis**

**In the anterior-inferior variety, which is the most frequent: pain, reduced movement, deformity of the shoulder, the arm abducted and externally rotated, and a reduced glenoid space.**

### **Look for complications**



**Ensure adequate pulses, finger mobility (brachial plexus), and sensation at the tip of the shoulder (circumflex).**

## **Treatment**

- **Reduction:** under general anesthetic (ketamine IM: 5 mg/kg) The patient lying on a table, counter-extension applied by an assistant holding a folded drape in the axilla, across the thorax and pulling towards the other shoulder. The operator places his stockinged foot in the axilla of the patient without pressing on the vascular/nerve bundle, and abducts the arm. A movement is felt as the humeral head re-enters the glenoid cavity.
- **Immobilisation:** 3 weeks in a sling in order to prevent recurrence.

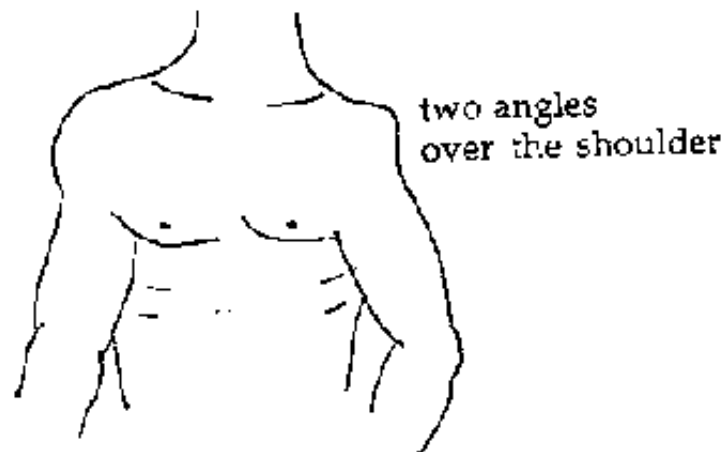
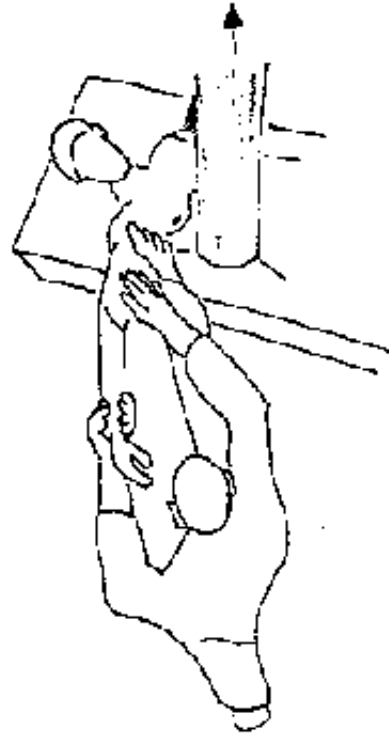
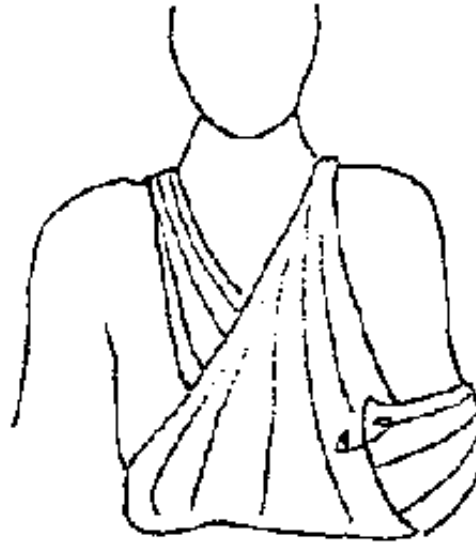

Figure 123

**FIGURE**



**Figure 124**  
**REDUCTION**  
**FIGURE**



**Figure 125**  
**IMMOBILISING SLING**  
**FIGURE**

## **Fracture of the neck of the humerus**

**Diagnosis Acute pain, reduced shoulder movement, swelling, large brachio-cephalic bruise, and the arm internally rotated (pathognomonic of this fracture).**

### **Look for complications**

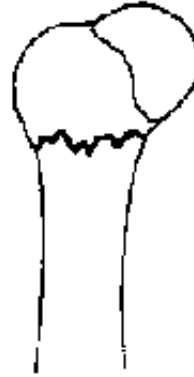**Damage to the vascular/nerve bundle in non-engaged fractures with displacement.**

### **Treatment**

**If the fracture is engaged without displacement, a support bandage for 15 days**

**and then physiotherapy.**

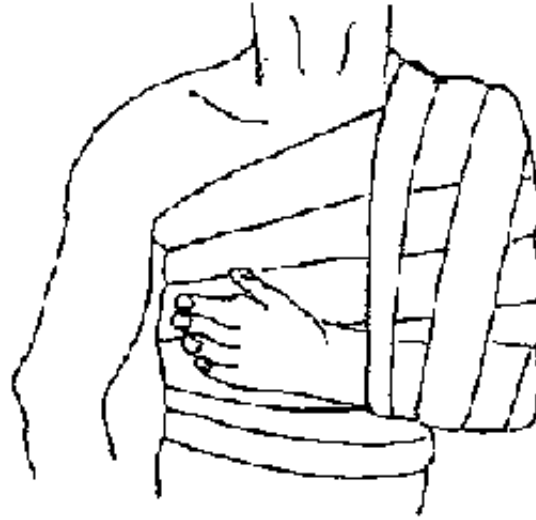
**If the fracture is displaced, it must be reduced under general anesthesia (ketamine IM) as with a dislocation, and immobilised with a support bandage.**



**Figure 126**  
*ENGAGED FRACTURE* of the neck  
of the humerus without displacement  
**FIGURE**



**Figure 127**  
*FRACTURE WITH DISPLACEMENT*  
**FIGURE**



**Figure 128**

A *SUPPORT BANDAGE* is made with perforated adhesive tape. Place cotton in the axillary creases to prevent friction. The bandage must be crossed vertically from the shoulder to the elbow and horizontally from the affected shoulder to the opposite wall of the thorax. There must be some mobility of the elbow, and the wrist must be completely free.

## **FIGURE**

### **Fracture of the shaft of the humerus**

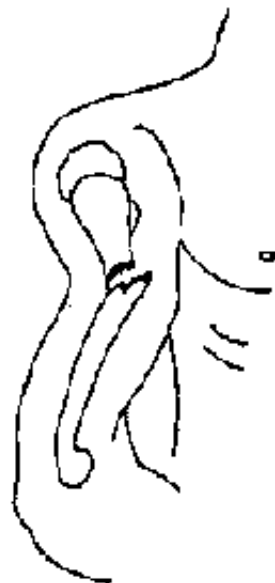#### **Diagnosis**

**Pain and reduced mobility. Shortening of the arm with angulation, usually antero-lateral. Brachial bruising.**

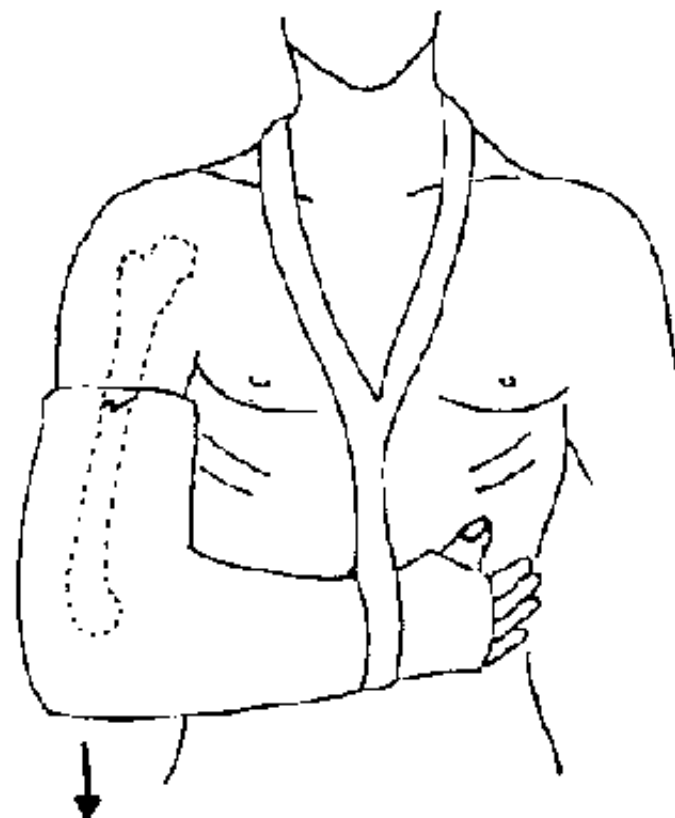
**Look for complications Paralysis of the radial nerve: inability to raise the hand.**

#### **Treatment**

**HANGING cast: brachio-ante-brachio-palmar, leave the upper part of the arm free and elevate the wrist with the plaster. This plaster should be set to correct the angulation, and should be maintained for 6 to 8 weeks.**



**Figure 129**  
**FRACTURE OF THE HUMERAL**  
**SHAFT**



**Figure 130**  
**HANGING CAST : make the plaster**  
**heavy and the plaster will then help to**  
**reduce the fracture. Fix the sling to the**  
**plaster to prevent slippage. Position the**  
**sling to reduce angulation.**

## **FIGURE**

### **Fracture of the lower humerus**

**A variety of supra-condular fractures are common in children.**

### **Diagnosis**

**Intense pain, reduced movement of the elbow.**

**The elbow is swollen, the fore-arm is shortened, but the triangle between the olecranon, epitrochlear and epicondyle is preserved.**

### **Look for complications**

**(Figures 131, 132)**

**There is a risk of compression to the humeral artery, and the median, cubital and radial nerves. Urgent reduction is necessary.**

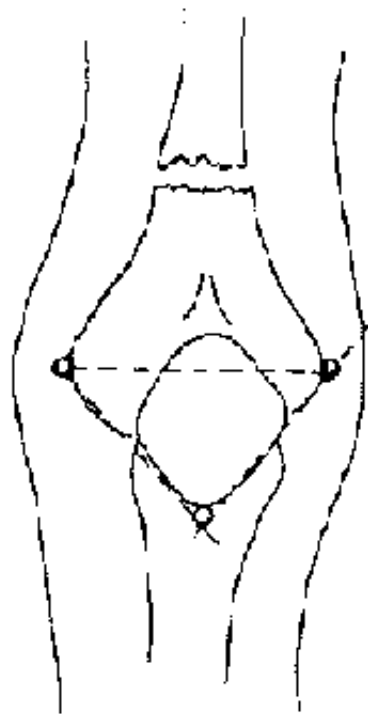
### **Treatment**

**(Figures 133, 134)**

**Reduction: under general anesthesia or local/regional anesthesia. An assistant holds the arm at a distance from the elbow. The operator takes the fore-arm with both hands and places it in pronation. Then traction should be applied along the axis of the humerus, followed by flexion of the elbow.**



● **Immobilisation with a POSTERIOR PLASTER SPLINT for 30 days.**

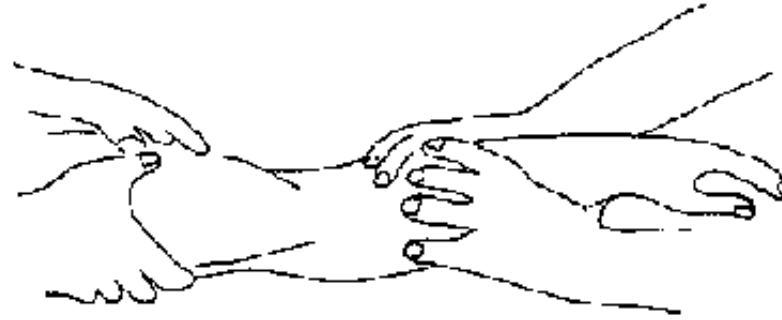


**Figure 131**  
*THE POINTS OF THE TRIANGLE*

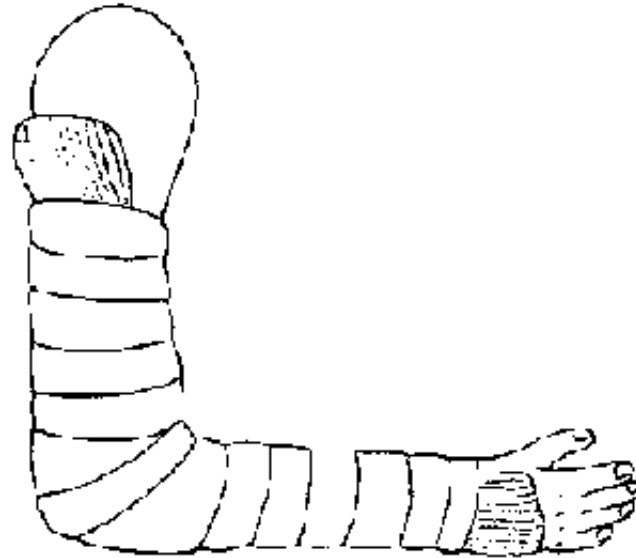


**Figure 132**  
*ANATOMY*

**FIGURE**



**Figure 133**  
TRACTION ALONG THE AXIS OF THE HUMERUS  
**FIGURE**



**Figure 134**

**POSTERIOR PLASTER SPLINT:** pad the elbow with cotton, wrap with a non-elastic bandage (not too tight). Regularly check the pulses and the nerves to prevent a Volkmann contracture. Support the splint with a sling.

**NEVER APPLY A CIRCULAR PLASTER!**

## **FIGURE**

### **Dislocation of the elbow**

#### **Diagnosis**

**Pain and reduced movement.**

**Deformed: thickening of the elbow, projection of the olecranon posteriorly, and shortening of the fore-arm.**

**The olecranon loses its normal conformity with the epitrochlear and the**

## **epicondyles: the isosceles triangle.**

### **Look for complications**

**Palpate the pulses, explore the territory of the 3 nerves and look for associated fractures.**

### **Treatment**

- **Manual reduction under general anesthesia (ketamine IM: 5 mg/kg) or local/regional anesthesia.**

**Place the two hands on the patient's arm and push with the two thumbs on the olecranon process (Figure 135a).**

**If this method fails, pull with both hands on the forearm of the patient, while an assistant applies counter traction with a sling passed in front of the upper arm, ensuring that it does not apply pressure to the flexor fold of the elbow (Figure 135b).**

- **Immobilisation for 2 to 3 weeks in a posterior plaster splint.**



Figure 135a

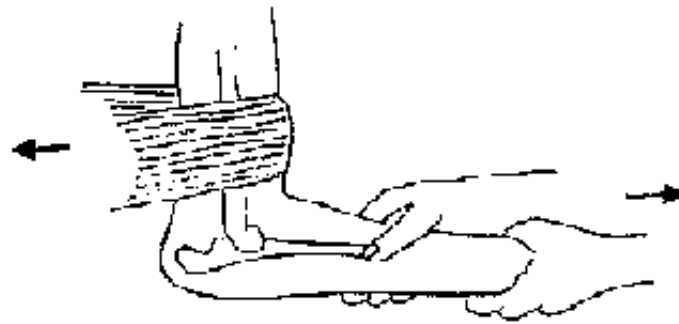


Figure 135b

Figures 135 REDUCTION OF AN ELBOW FRACTURE

## FIGURE

### Fracture of the two bones of the fore-arm

#### Diagnosis

**Pain, reduced movement, some deformity, and sometimes shortening.**

#### Look for complications

**The fracture is often open, requiring cleaning, dressing and antibiotic therapy (for example in an adult, ampicillin: 4 g/day in 4 doses for 5 days).**

**Check pulses, explore the nerves (radial, raise the fingers, separate and then bring the finger together).**

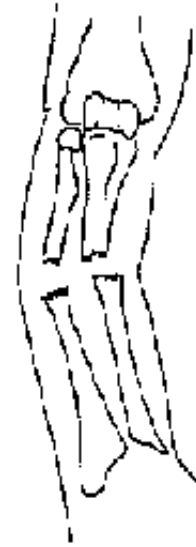## **Treatment**

**In a child it is possible to reduce the fracture and then plaster, but in an adult, the treatment is usually surgical because of the formation of callus under the plaster which ultimately limits pronation and supination.**

- **Reduction under general anesthetic or regional/local anesthetic. This reduction is easy in a child: traction on the hand by the operator while the assistant applies counter-extension to the flexed elbow.**
- **Immobilisation plaster (Figures 136,137) Elbow at right angles, protected in the flexural fold with cotton, the hand midway between pronation and supination, the plaster covering the brachio palmar surface as far as the metacarpal joints, leaving the fingers free. IMMEDIATELY SPLIT THE PLASTER. Immobilisation: 3 months for an adult, 45 days for a child.**



Shortening



Angulation

Figure 136  
**FIGURE**

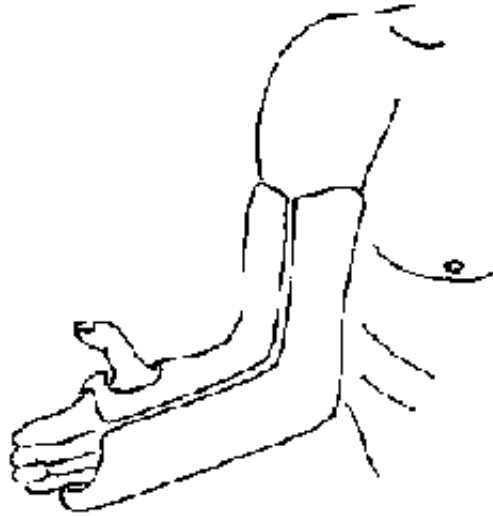


Figure 137  
*BRACHIO-PALMAR PLASTER, elbow at right angles, thumb up and free plaster split.*

## FIGURE

### Fracture of the distal radius

Colles fracture is the most frequent.

### Diagnosis

Pain, reduced movement of the wrist. Characteristic "bent fork" deformity of the wrist (Figure 138).

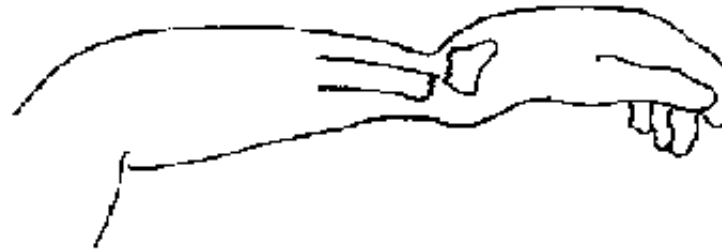
### Treatment

- Reduction under general anesthesia or local/regional anesthesia. Local

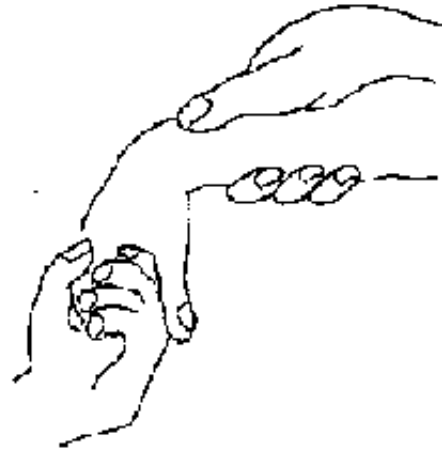


**anesthesia is possible following rigorous aseptic technique. Inject 10 ml of 1% lidocaine into the hematoma of the fracture. The left hand of the operator takes the patient's fingers and applies axial traction. The thumb of the right hand presses on the back of the bent fork deformity. Then, flex the palm of the hand and incline it cubitally (Figures 139a, 139b).**

**• Immobilisation for 30 days in a forearm plaster, the wrist in a neutral position. This plaster must leave the metacarpal phalangeal joint of the thumb free and should reach the metacarpal phalangeal joints of the other fingers (Figure 140a). If surveillance of the plaster cannot be assured, do not cover the elbow with the plaster (Figure 140b).**



**Figure 138**  
**DIAGNOSIS: bent fork deformity**  
**FIGURE**



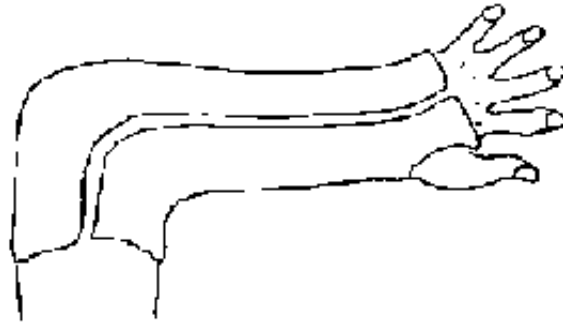
**Figure 139a**  
**Palmar flexion and**  
**cubital inclination**



**Figure 139b**

**Figures 139 : REDUCTION OF THE FRACTURE**

## **FIGURE**



**Figure 140a**  
Split forearm plaster



**Figure 140b**  
Ante-brachio-palmar plaster  
free thumb

**Figures 140 : IMMobilISATION PLASTER**

## **FIGURE**

### **Fracture of the scaphoid**

**(Figure 141)**

#### **Diagnosis**

**Difficult to diagnose without an X-ray. Pain on pressing the anatomical snuff box, pain on traction and pressure at the base of the thumb.**

#### **Treatment**

**Split brachio-palmar plaster, covering the proximal two phalanges of the thumb, and maintained for 6 weeks.**

## **Anterior dislocation of the lunate**

### **Diagnosis**

**(Figure 142)**

**Difficult without an X-ray. Pain, reduced movement of the wrist, no bent fork deformity, the wrist is thickened and sometimes there are pins and needles from compression of the median nerve.**

### **Treatment**

**(Figure 144)**

**Under general anesthetic, traction on the fingers for 30 minutes or more, after which the dislocation will reduce itself. Then maintain immobilised in an anterior splint for 20 days.**

## **Dislocation of the carpus**

### **Diagnosis**

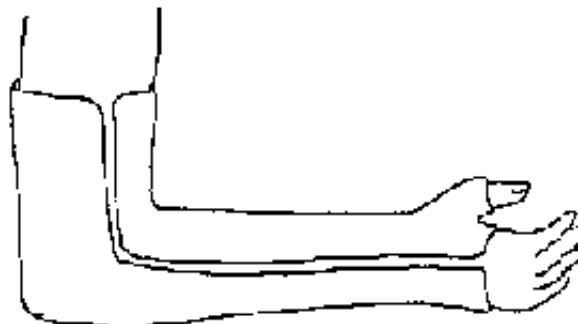**(Figure 143)**

**Difficult without an X-ray. Pain and immobility of the wrist, the distal ends of the radius and ulnar are in position on palpation, but there is a "bent fork deformity" at the level of the carpal bones.**

### **Treatment**

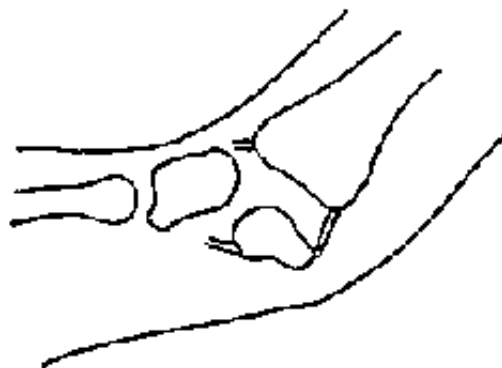**(Figure 144)**

**The same principles apply as for reduction of a dislocation of semi-lunaris.  
Immobilise in an anterior splint, wrist to the right, fingers flexed, thumb free.**



**Figure 141**  
*SCAPHOID FRACTURE* : brachio-palmar covering the proximal phalanges of the thumb, and split

**FIGURE**

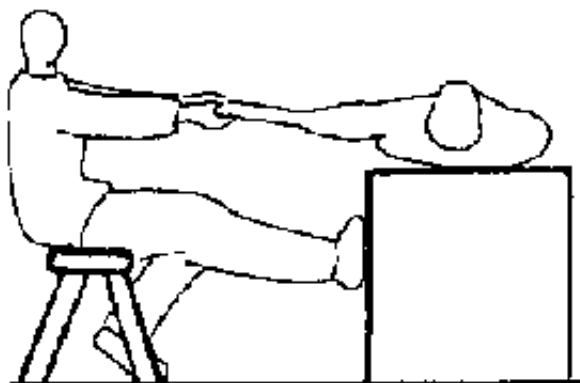


**Figure 142**  
*DISLOCATION OF THE LUNATE*

**FIGURE**



**Figure 143**  
*DISLOCATION OF THE CARPUS*  
**FIGURE**



**Figure 144**  
*REDUCTION : continuous traction on the fingers*  
**FIGURE**

## **Fractures of the metacarpals and phalanges**

## **Diagnosis**

**Sometimes difficult, masked by developing edema around the fracture, especially in the case of a fractures of a metacarpal: deformity, angulation, rarely shortening.**

## **Treatment**

**(Figures 145,146, 147)**

- **Reduction of the fracture by simple alignement, under local anesthesia, local/regional or general anesthesia.**
- **Immobilisation using a "ball made with plaster of Paris": the operator makes a ball out of plaster and it is held in the palm of the hand. The fractured finger is strapped to the ball with an adhesive tape. In cases of a fracture of a metacarpal, the ball is first fixed to an anterior forearm splint which is held in position with a bandage leaving the fingers free.**

**The hand and fingers should be immobilised in a functional position.**



Figure 145  
FUNCTIONAL POSITION for immobilisation of the hand and fingers

**FIGURE**



Figure 146  
"BALL MADE WITH PLASTER OF PARIS" for fracture of a finger

**FIGURE**






Figure 147  
IMMOBILISATION by means of an anterior splint  
under the "ball of plaster of Paris"

## FIGURE

### Trauma of the lower limb

#### Fracture of the neck of the femur

#### Diagnosis

**In general the clinical signs are easy: shortening of the limb, external rotation of the buttock, impossible for the patient to lift the leg into decubitus.**

#### Treatment

**Traction for 90 days for an adult.**

#### Fracture of the shaft of the femur

## **Diagnosis**

**Obvious signs: shortening of the thigh, deformity, huge hematoma (watch out for "shock"!).**

## **Treatment**

**Traction-suspension for 90 days for an adult. Do not forget to look for complications: pulses, nerves, contaminated wound. Give antibiotic therapy if the fracture is open.**

## **SUSPENDED SKIN TRACTION**

**(Figure 148)**

**In the absence of material (transtibial wire), skin traction can be applied using a bandage attached to the skin by large bands of non elastic adhesive tape, applied along, not around the limb, from the thigh to the heel and connected to a board maintaining the ankle at right angles to prevent a resulting deformity.**

**The board is attached to a cord which is suspended, by weights of 1/7 body weight, on a pulley. Traction should be in the axis of the limb, counter traction coming from the patient resting in bed at an angle of 45° to the horizontal.**

**In adults, it is difficult to maintain this traction for 3 months: the state of the skin must be checked each day, the bandages will become unstuck and will need changing. If this traction is impossible to maintain, it can be replaced with a pelvic-leg plaster, for the remainder of immobilisation, but as late as possible, for example on the 45th day. This type of traction not only produces a reduction of the**

**fracture but also allows the quadriceps muscle to be exercised.**

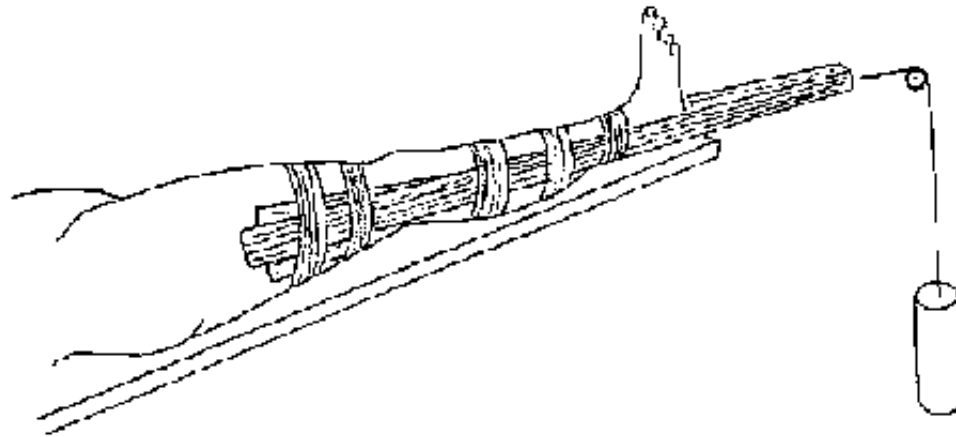


Figure 148  
SKIN TRACTION: counter-traction from the weight of the patient inclined at 45°

## FIGURE

### TRACTION FOR CHILDREN

(Figures 149a, 149b)

#### Indication

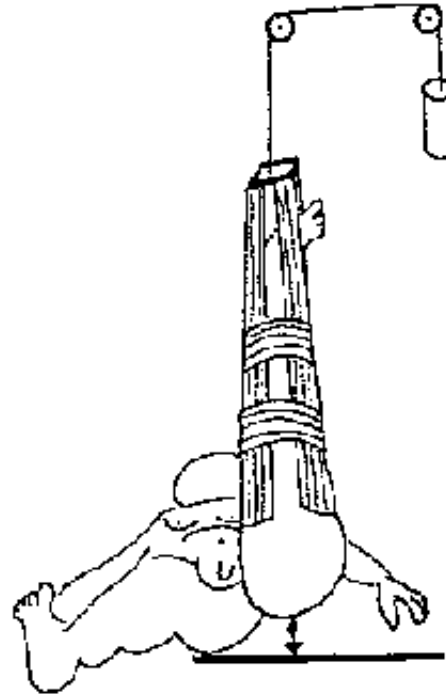
**Fracture of the femur in children aged 8 - 10 years.**

#### Technique

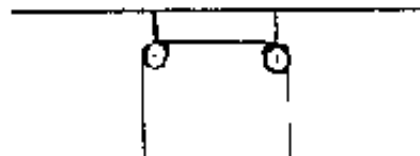
**The same principal as for skin traction in the adult, but the limb is suspended vertically by a weight equivalent to 1/7 of the child's body weight, the buttock elevated above the lying position (gallow's traction).**

**Construct a frame passing above the bed from which a pulley can be hung.**

**This traction is maintained for 3 weeks and is then replaced with a pelvic-leg plaster for 15 to 20 days (Figures 150,151,152).**



**Figure 149a**  
The buttock is elevated above the bed



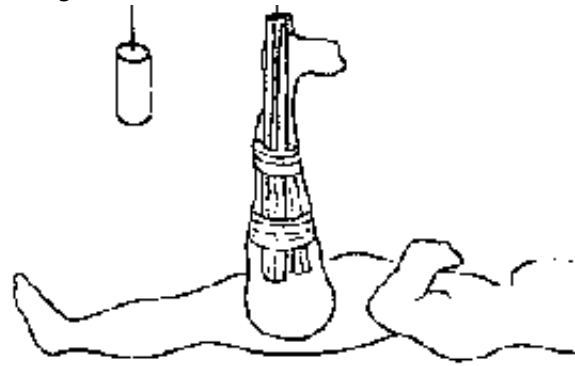


Figure 149b

Figures 149 : GALLOW'S TRACTION

FIGURE

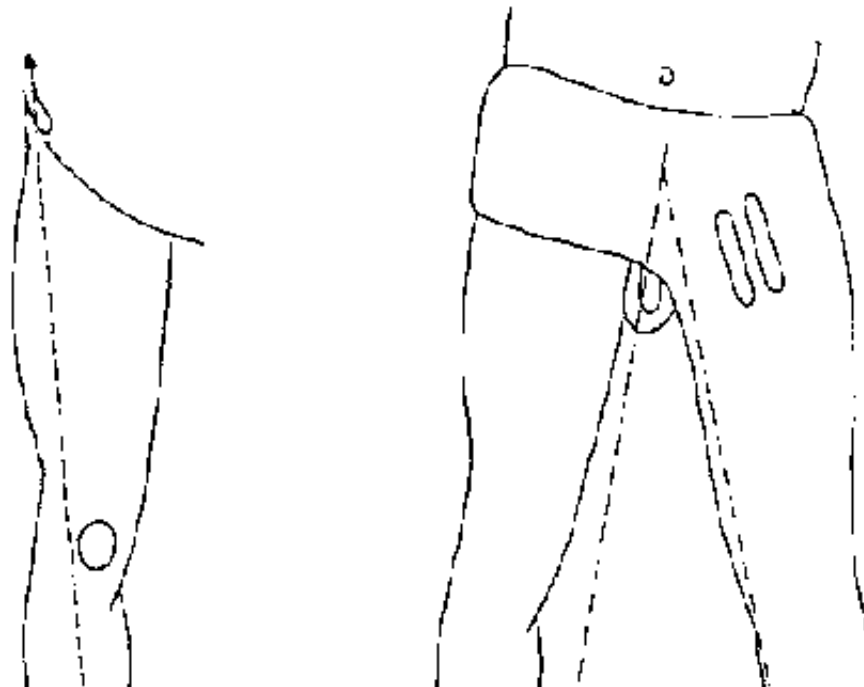

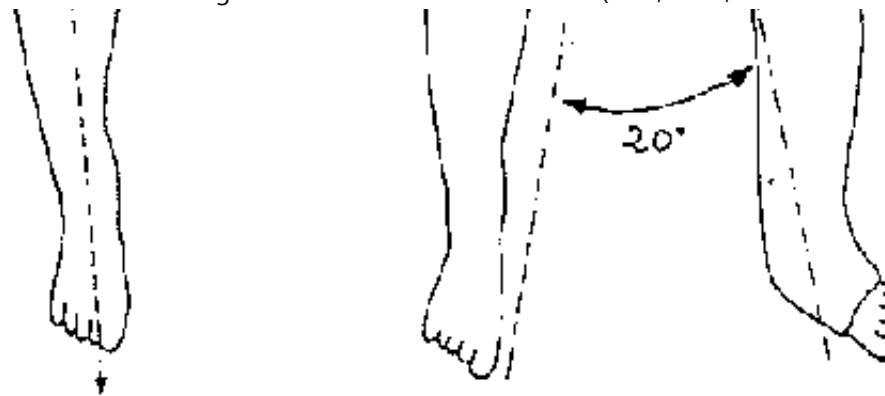


Figure 150  
ALIGNMENT OF THE  
LOWER LIMB

Figure 151  
PELVIC-LEG PLASTER, reinforced  
at the hip

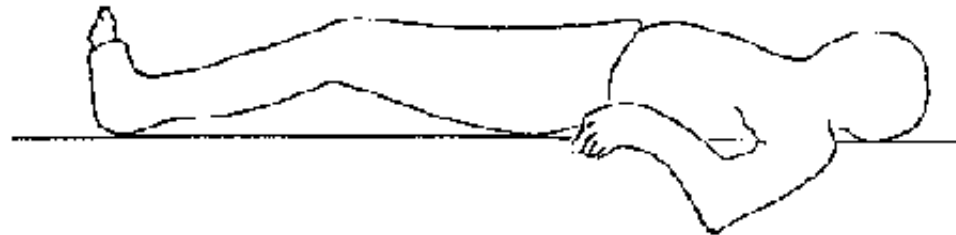


Figure 152  
KNEE FLEXED AT 15° - ANKLE AT RIGHT ANGLES

## FIGURE

### MAKING A PELVIC-LEG PLASTER

#### Indications

#### Fractures of the femur

#### Technique

**Requires several assistants, 3 if possible, to maintain the alignment of the limb (the line passing between the anterior superior iliac spines, the edge of the patella and the first interdigital space), the knee flexed at 15° and the ankle at right angles.**

**Start with a plaster splint positioned posteriorly which will reinforce the plaster.**

**Do not forget to protect the skin folds and the bony prominences with cotton.**

**Build up the plaster with small splints at the level of the articulation of the thigh.**

**Find a way of supporting the crutch in order to be able to unroll the plaster bandages around the pelvis.**

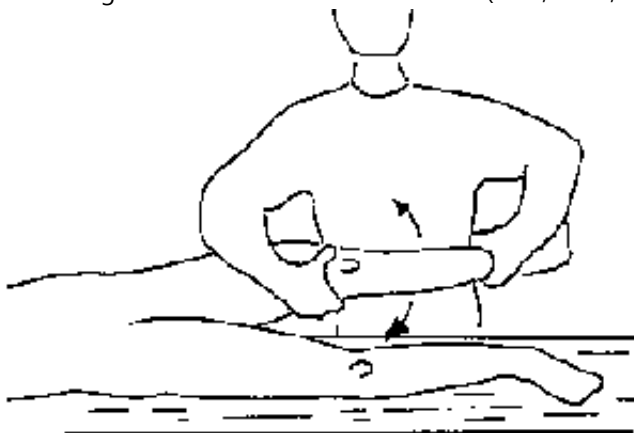
**The plaster must cover the two anterior-superior iliac spines, be supported on the sacrum, and must be free of the anus and perineum. The toes should be uncovered to allow good surveillance of the plaster.**

**Torsion of the knee**

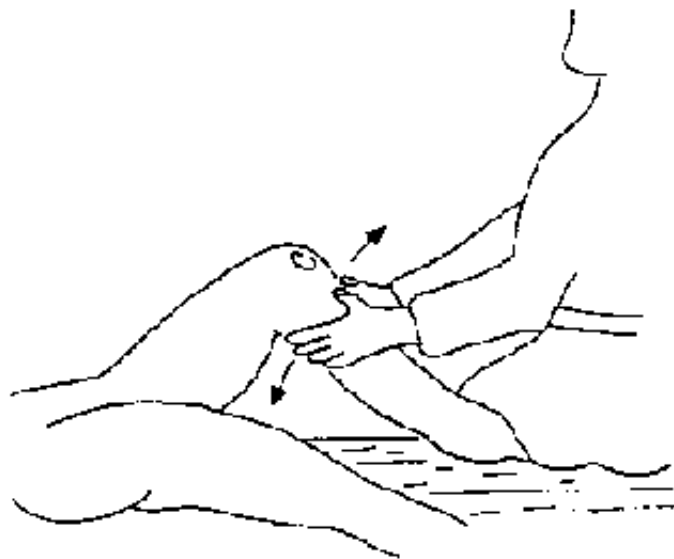
**All damage to knee ligaments.**

**Diagnosis  
(Figures 153,154, 155)**


**Hemarthroses, interarticular pain, abnormal lateral or antero-posterior movements.**



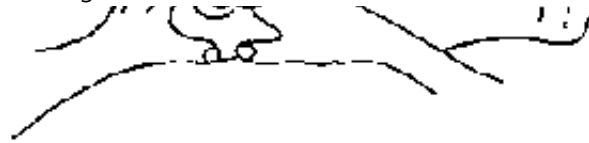
**Figure 153**  
SEVERE KNEE TORSION: look for lateral movement



**Figure 154**  
LOOK FOR ANTERIOR-POSTERIOR MOVEMENT







**Figure 155**  
*LOOK FOR A HEMARTHROSIS*

## **FIGURE**

### **Treatment**

**If hemarthrosis is severe, apply a posterior plaster splint supported with a noncompressing bandage. After 48 hours, drain the, hemarthrosis and place the limb in a knee cylinder which should be split from the buttock to the ankle, the knee flexed at 15°. The plaster should remain for 45 days in severe cases (abnormal knee movements)**

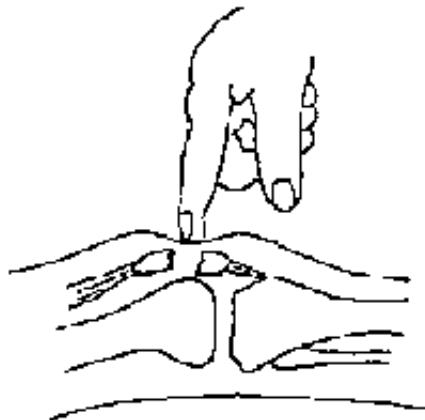
### **Fracture of the patella**

#### **Diagnosis**

**Easy in the case of a displaced fracture by detecting depression between the two fracture fragments.**

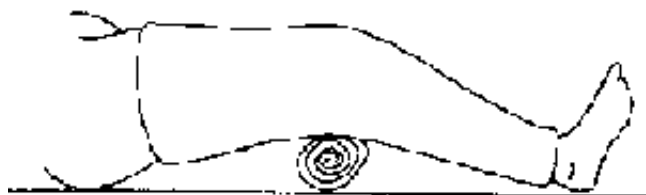#### **Treatment**

**Surgical if possible, otherwise a knee cylinder plaster for 45 days.**

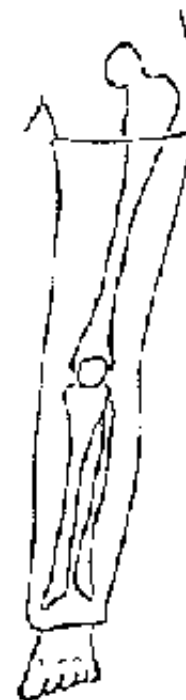

**Figure 156**  
*FRACURE OF THE PATELLA* : depression detected between the two fragments

**FIGURE**



**Figure 157a**  
knee flexed at 15°



**Figure 157b**

**Figures 157 : KNEE CYLINDER**

## **FIGURE**

### **Fracture of the two leg bones**

#### **Clinical diagnosis**

**Usually obvious: deformity, shortening and angulation.**

#### **Treatment**

**(Figures 158a to 160)**

- **Reduction under general anesthesia (ketamine 1M: 5 mg/kg). By the method of "hanging leg": the patient lying on a table, the fractured leg hanging over the edge, the operator facing the patient and supporting the heel of the damaged leg on his knee. Vertical traction is applied (majoring the effects of gravity) to reduce the fracture. The operator's thumb should be placed on the tibial shaft to control the reduction.**

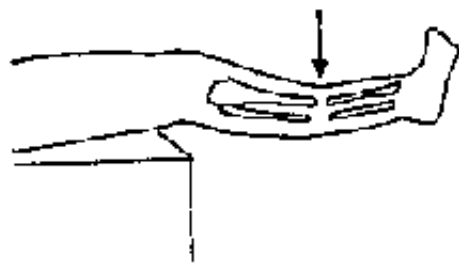
#### **- Immobilisation:**

**The lower leg plaster should be applied from the knee to the ankle with the knee at right angles. When this part of the plaster is dry, the leg should be rested on the table to apply the thigh plaster, knee in 15° flexion with toes uncovered.**

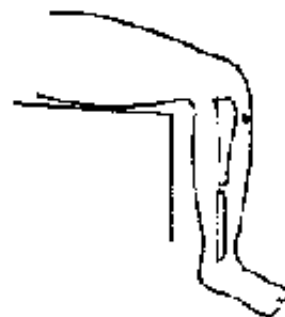**This plaster should be maintained for 90 days in adults and 60 days in children under 10 years of age.**

**If there is an open fracture:**

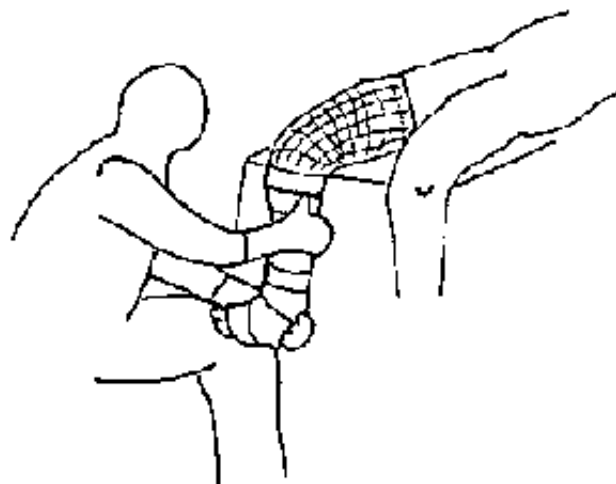
- **General anesthetic (ketamine) if the patient is fit.**
- **Treat the wound in the best possible aseptic conditions (operating theater, using sterile drapes and gloves etc.)**
- **Remove foreign bodies, excise bone splinters and necrotic tissue, and clean abundantly with chlorhexidine (+ cetrimide) (see table page 7).**
- **If the wound is recent and clean, attempt to close the skin.**
- **If skin tissue is lacking, cover the wound with sterile vaseline compresses and soak with polyvidone iodine (see table page 7).**
- **If possible, give anti-tetanus prophylaxis and systemic antibiotic therapy (procaine penicillin or PPF: 5 MUI/day for at least 5 days, or ampicillin: 3 or 4 g/day in an adult).**
- **Immobilise on a plaster splint (not a circular plaster to begin with)**
- **Apply regular dressings under strict aseptic conditions.**
- **As soon as the wound is healing, the splint can be changed for a circular plaster with a window cut over the wound to allow external care.**



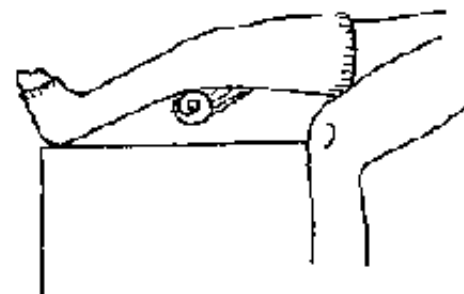
**Figure 158a**  
**FRACTURE OF THE LEG : reduction with leg over the side of a table**



**Figure 158b**



**Figure 159**



**Figure 160**  
**LOWER LEG PLASTER : knee flexed at 15 °, ankle at right angles**

## **FIGURE**

### **FRACTURE OF THE ANKLE**

#### **Diagnosis**

**Easy when there is internal or external subluxation of the malleolus. More difficult when there is an isolated fracture without displacement of the malleolus. Look for discomfort while balloting the ankle bone and moving the foot in a transverse direction (the left hand holding the leg, the right hand supporting the heel and instigating the movement).**

#### **Treatment**

- **Reduction under general anesthesia (ketamine IM 5 mg/kg) with the "removing shoe" maneuver: a hand on the leg, the other supporting the heel and reduce the fracture with the same movement as removing a shoe (Figures 161, 162).**
- **Immobilisation (Figure 163)**

**In an ankle plaster, well applied over the malleolus and holding the foot at right angles for 60 days, without weight bearing.**



**Figure 161**  
**FRactURE OF THE ANKLE :**  
look for discomfort when  
balloting the ankle bone



**Figure 162**  
**REDUCTION OF AN ANKLE**  
**FRactURE :** "removing shoe"  
maneuver



**Figure 163**  
**ANKLE PLASTER :** well moulded around the malleoli, with ankle at right angles

## FIGURE

### Period of immobilization for major fractures

<b>Table 5:</b>	<b>Bone</b>	<b>Adult in days</b>	<b>Children &lt; 10 yrs in days</b>
	Clavicle	21	21
	Neck of the humerus	15	15
	Shaft of the humerus	60	60
	Supracondylar fracture	45	45
	Two bones of forearm	90	45
	Distal radius	30	30
	Scaphoid	45	45
	Metacarpal	30	21
	Phalanx	30	21
	Neck of the femur	90	60
	Shaft of the femur	90	60
	Two bones of the leg	90	60
	Ankle	60	60
	Metatarsals	15	15

**TABLE 5**



## **SPRAINED AND TORN ANKLE LIGAMENTS**

### **Diagnosis**

**The differential diagnosis is with a non displaced fracture of the ankle: edema, pain over the external lateral ligament, and look for ballottement of the ankle bone.**

### **Treatment**

**In all cases, below knee walking cast, for 21 days.**

## **FRACTURE OF A METATARSAL**

### **Diagnosis**

**Difficult, but sometimes obvious especially with fracture of the 5th metatarsal.**

### **Treatment**

**Below knee walking cast for 15 days.**

## **FRACTURE OF THE TOE**

### **Diagnosis**

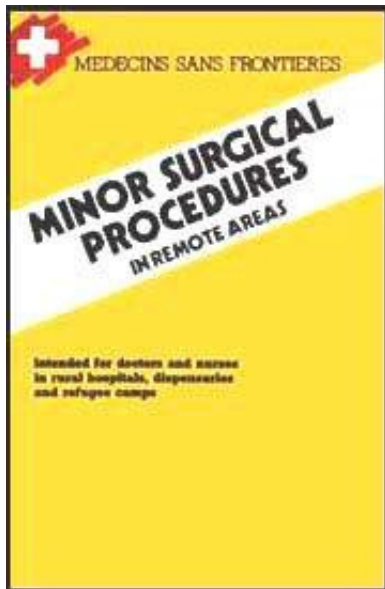
**Usually obvious: hematoma, displacement.**

### **Treatment**

**Reduction under local anesthesia if necessary, and splint the fractured toe to the adjoining toe with adhesive tape. The same conditions apply as for dislocations.**

**Orthopedic treatment (see table 5)**

[Home](#) > [ar.cn.de.en.es.fr.id.it.ph.po.ru.sw](#)



- 📖 **Minor Surgical Procedures in Remote Areas (MSF, 1989, 172 p.)**
- ➔ 📄 **Appendix**
  - 📄 **List of essential supplies (absolutely necessary)**
  - 📄 **Disinfection and Sterilization of medical equipment and supplies**

**Minor Surgical Procedures in Remote Areas (MSF, 1989, 172 p.)**

**Appendix**

**List of essential supplies (absolutely necessary)**

**Must be carried along by any moving to dispensary**

- **Set of IV placement canula (size 16 to 22 G)**
- **Infusion giving set disposable, and needle, with different available solutions**
- **CPD bags, phlebotomy set with disposable needles, serum tests**
- **Pleural or spinal needle disposable**
- **Thoracic drain**
- **Urinary catheter (size CH 12 to CH 18) with urine collecting bag**
- **Sus-pubien catheter with trocar and mandrin**
- **Dental box with dental forceps, syndesmotome and syringe for dental anesthesia**
- **Sterile "basic surgery" set (to see next page)**
- **"Dressing" set (to see next page)**
- **"Abscess/suture" set (to see next page)**
- **Sterile "curetage" set (to see next page)**
- **Sterile gloves (several pairs)**
- **Drum of sterile compresses**
- **Drum of sterile towels**

- **Sterile gauze impregnated with paraffin**
- **Adhesive tape (punched) 18 cm x 5 metres: 2 rolls**
- **At least 2 sutures synthetic non absorbable Dec 1**
- **At least 3 sutures synthetic non absorbable Dec 2**
- **At least 3 sutures synthetic non absorbable Dec 3**
- **At least 2 sutures absorbable Dec 1**
- **At least 2 sutures absorbable Dec 3 (Vicryl©, Ercedex©, Dexon©, Ligadex©)**
- **Suture needles assorted sizes, straight, curved, triangular and round point**
- **Polyvidone iodine and chlorhexidine 1,5 % + cetrimide 15 % (solution concentrated)**
- **At least 5 rolls of plaster of paris bandage (15 cm x 2,75 m)**
- **Plaster scissors**
- **One roll of bandage tricot tubular (5/6 cm x 25 m)**
- **One roll of bandage tricot tubular (10/12 cm x 25 m)**
- **Cotton wool, 1 kg**

- **Sterile needles and syringe**
- **Sterile caoutchouc and corrugated drain**
- **One otoscope and one paracentesis needle**
- **2 vials of lidocaine 1 % (no epinephrine)**
- **3 vials of ketamine (250 mg to 50 mg/ml)**
- **1 vial of ketamine (250 mg to 10 mg/ml)**
- **Pulley with hook**
- **Small nylon cord**

### **Dressing set**

Stainless steel box, 17 x 7 x 3cm	1
Surgical scissors, straight sharp/blunt, 12-14 cm	1
Kocher forceps, no teeth, straight, 12-14 cm	1
Dissecting forceps, no teeth, 12-14 cm	1

### **Abscess/suture set**

Stainless steel box, 22 x 10 x 5 cm	1
Dissecting forceps, with teeth, 12-14 cm	1

Kocher forceps, teeth, straight, 12-14 cm	1
Pean forceps, straight, 14 cm	1
Surgical scissors, curved, sharp/blunt, 12-14 cm	1
Probe, 14-16 cm	1
Mayo-Hegar needle holder, 18 cm	1
Handle scalpel n°4	1

## Basic surgery set

Stainless steel box, 25 x 10,5 x 5 cm	1
Handle scalpel n°4	1
Mayo-Hegar needle holder, 18 cm	1
Surgical Mayo scissors, curved, 14 cm	1
Surgical dissecting Metzemabaum scissors, curved, 14 cm	1
Farabeuf retractors, short	2
Small artery forceps (Halstead = mosquitos), no teeth, curved, 12 cm	4
Kocher forceps, with teeth, straight, hemostatic, 14 cm	2
Probe, 14,5 cm	1
Dissecting forceps, with teeth, 14 cm	1
Dissecting forceps, no teeth, 14 cm	1
Hemostatic forceps (Chaput), 14 cm	2
Hemostatic forceps (Collin), 16 cm	1

Towel clips (Backaus), 10 cm	1
Gallipot, 18 cm	1

## Curetage set

Stainless steel box, 40 x 20 x 10 cm	1
Sponge holding forceps (Cheron), straight, 25 cm	1
Vulsellum forceps (Muzeux), 24 cm, teeth 10 mm	1
Vaginal retractor (Doyen), straight, 85 x 45 mm	1
Weighted vaginal speculum (Jayle)	1
Uterine sound (Sims)	1
Blunt curette (Simon), 6 mm	1
Blunt curette (Gourdet), 12 mm	1
Gallipot, 8 cm	1
Uterine dilators, set of 13, n° 1/2 to 25/26	1
Vaginal speculum (Collin), 100 x 35 mm (or 110 x 40 mm)	1

## Disinfection and Sterilization of medical equipment and supplies

- **Sterilization = elimination of all micro-organisms (viruses, microscopic fungi, bacteria, both vegetative and spore forms).**
- **Disinfection = elimination of most micro-organisms present on a surface or object.**

- **Decontamination = disinfection of object soiled by infectious material (pus, blood, excrete, etc.).**

## **General rules**

### **All equipment or supplies:**

- **coming into contact with sterile parts of the body (injection equipment, surgical instruments, some dressings, catheters.).**
- **used for perfusion. should be sterilized and kept sterile until utilization.**

**All reusable items, which do not correspond to the above definition, but which come into contact with mucus membranes, or get soiled with pus, blood, lymphatic or vaginal secretions, should be sterilized or subjected to a high level disinfection (effective among others against HIV and hepatitis B virus).**

**All soiled, non reusable equipment should be incinerated (warning: never recap needles after use = main cause of accidental needlestick).**

**To carry out proper sterilization is not always easy in the field conditions of isolated rural medical centers. It requires proper appliances (autoclave, hot air sterilizer), and an energy source.**

**In practice, one is often obliged to use alternative procedures which are not wholly satisfactory as they produce disinfection rather than sterilization (They are however compulsory if one cannot do better) (see following chapters).**



**Disinfection and sterilization of medical equipment is not enough to prevent iatrogenic infections (resulting from medical practice). It is obvious that basic hygienic and asepsis techniques ought to be applied: cleaning and disinfection of surfaces and premises, personal hygiene of the staff, aseptic handling of sterilized instruments, etc.**

### **Cleaning of reusable equipment**

**Soiled items and instruments should be carefully cleaned before being sterilized or subjected to a final disinfection.**

**The presence of organic matter could protect germs against the action of a disinfectant or sterilizing agent, or could react against it, rendering it ineffective.**

### **Instruments**

**Cleaning can be done either with water alone, with water and soap (or detergent), or with water and a compound of disinfectant/detergent.**

**Cleaning with a disinfectant chemical aims mainly to reduce the risks of contamination for the staff, but it does not eliminate them completely.**

**The staff in charge of instrument cleaning should be aware of the contamination risks (AIDS, hepatitis B), they should wear thick plastic or rubber gloves, and be careful when they handle sharp instruments.**

**After use and before cleaning, all instruments and items should be soaked in water to avoid deposits drying up. A disinfectant could be added for a first**

**decontamination (chloramine 20 g/l, lysol 50 g/l).**

**Metallic instruments can be damaged if they are left in water too long (over several hours) or if the disinfectant concentration is too high.**

**Note:**

**Needles and syringes for immunization should be soaked and cleaned with water alone, as traces of soap and disinfectant can inactivate vaccines.**

**After cleaning, instruments and items should be rinsed thoroughly with water and dried, then sterilized, boiled or disinfected (with a high level disinfectant) depending on their use and the local sterilizing facilities.**

**Linen and dressing**

**To decontaminate linen and dressings, one should wash them with an ordinary washing powder (eg. OMO) and boil them if possible (5 minutes).**

**If boiling is not possible, linen should be washed, rinsed and soaked for 30 minutes, in a 0.1 % chlorine solution (hypochlorite, bleach, chloramine), or 5 % lysol solution. It should then be rinsed abundantly and dried.**

**Theatre linen should be sterilized in an autoclave or ironed depending on local facilities.**

**Sterilization methods and alternatives**

## **Autoclaving**

**Sterilisation by steam under pressure in an autoclave.**

**Autoclaving is the most reliable sterilization method and the only one that allows effective sterilization of all medical equipment and supplies (especially linen and rubber). But relatively sophisticated appliances and energy source (electricity, kerosene or gas) are needed.**

**It is based on the same principle as a kitchen pressure cooker. Because water is heated in a closed container, temperatures above 100°C can be reached.**

**In the absence of air (air is purged at the beginning of sterilization), the temperature can be regulated by controlling the pressure.**

**According to the type of supply to be sterilized, sterilisation is carried out at 121°C (1 atmosphere over atmospheric pressure) or at 134°C (2 atm. over atmospheric pressure).**

Items to be sterilized	Temperature		Pressure*		Duration**
	°C	°F	Atm., Bar or kg/cm <sup>2</sup>	PSI	
Instruments, syringes, plastic, glass, rubber	121	250	1	15	30'
Dressing (swabs), linen (gowns, drapes...)	134	275	2	30	20'
	Otherwise 121	250	1	15	40'

\* Over atmospheric pressure  
 \*\* Add 5 minutes per 1000 meters above sea level

**TABLE 6****Note:**

- Do not forget to expell air (purge) while increasing the pressure (otherwise the temperature in the autoclave will not be sufficient).
- Drums or boxes holding objects to be sterilized must be open, never closed (unless fenestrated). The sliding windows in the special autoclave boxes should also be open during sterilization.
- Count the sterilizing time from the moment the required temperature or pressure is reached, not from the start of the heating phase.

**Dry heat (in hot air sterilizer or oven - called a Poupinel in french)**

**Sterilization by hot air (dry heat) at 160°C (320°F) for 2 hours or at 170°C (340°F) for 1 hour.**

**Reliable method provided it is carried out in a good electric appliance with working thermometer (an air circulation device is needed in large ovens).**

**This method is convenient for metal, heat resistant glass, and vaseline, but is not convenient for linen or gauze swabs. The oven method is quite simple but consumes more energy than an autoclave.**

**Ovens heated by charcoal fires or kerosene heaters are not reliable because they do not produce a sufficiently high temperature.**

**Time should be calculated from the moment the required temperature is reached (this is very important).**

### **Notes:**

- **Begin heating with the door open to expel any humidity (which could rust instruments).**
- **Do not exceed 170°C (could damage metallic instruments).**
- **It is better to place items in dosed boxes. However, large boxes should be left half-open to allow the material to more rapidly achieve the correct temperature.**

### **Boiling**

**Boiling for 20 min (adding 5 minutes for 1000 altitude) provides high level disinfection, but not sterilization because it does not destroy bacterial spores (eg.: tetanus, gangrene).**

**Boiling is nevertheless essential when autoclaving or hot air sterilization are not possible. It is particularly useful for needles and syringes (it destroys HIV and hepatitis B virus).**

**After needles and syringes have been boiled, they should be kept dry and not left in the water (which can easily become recontaminated).**

## **Flaming**

- **In a flame: Effective if instruments are made red hot. This method should only be used in exceptional circumstances as it damages metal.**
- **With alcohol: Instruments are dipped in alcohol and set alight. This method is unreliable, expensive and in the long term damages instruments.**

## **Ironing**

**Surgical drapes and gauzes can be ironed if an autoclave is either unavailable or too small to hold large operating drapes.**

**Iron on a table or bench covered with a sheet that has itself just been "sterilized" by ironing.**

**Dampen each item slightly with filtered boiled water.**

**The iron should be very hot and passed several times over each side of linen/gauze.**

**However, if it is available, autodaving is always the preferred method.**

**Immersion in "high level" disinfectants**

**Immersion (of clean equipment) in the following disinfectant solutions destroys bacteria and virus including HIV and hepatitis B virus. The bacterial spores are generally not destroyed.**

**This process could be used as an alternative to sterilization when autoclaving or hot air sterilization are not possible.**

**Boiling however is always preferred. The effectiveness of chemical disinfection can always be impaired by dilution errors, by bad storage conditions, or by prolonged utilization of the same solution (solutions should be renewed at least once a day).**

**Chemical disinfection should never be recommended for syringes and needles.**

<b>Table 7</b>	<b>Recommended Concentration</b>	<b>Preparation</b>	<b>Minimal contact</b>	<b>Note See below</b>
Hypochlorites	0.1 % available chlorine (1,000 ppm)	see note 1	15 min.	2
Tosylchloramide Chloramine T	2 %	20 g/litre	15 min.	3
Polyvidone iodine (Povidone iodine PVI)	2.5 %	1 part 10 % concentrated solution (eg. Betadine <sup>®</sup> ) + 3 parts water	15 min.	3
Ethanol	70 %	8 parts ethanol 90 % + 2 parts water	15 min.	4
Isopropanol	70 %	7 parts isopropanol + 3 parts water	15 min.	4
Formaldehyde	4 %	1 part formalin + 3 parts water	30 min.	5
Glutaraldehyde	2 %	Addition of the activator supplied with the solution	30 min.	5

**TABLE 7**

**1. Hypochlorite solution (0.1 % or 1,000 ppm - 1ppm = 1part per million = 1mg/ml = 0.0001% - available chlorine) is prepared either from liquid bleach recently manufactured (< 3 months) or from calcium hypochlorite or from sodium**



**dichloroisocyanurate (NaDCC, "Javel tablets", Javel solid, Stafilex, Actisan.), diluted according to their respective available chlorine content.**

**Fresh liquid bleaches contain 3 to 15 % available chlorine (sometimes expressed in chlorometric degrees, 1° chlorom. = approx. 0.3 % available chlorine). Calcium hypochlorite contents from 30 to 70 % available chlorine.**

**The NaDCC based tablets contain generally 1.5 g available chlorine per tablet (1 tablet per litre = 1,500 ppm available chlorine). NaDCC withstands heat much better than bleach and calcium hypochlorite.**

**2. As hypochlorite solutions are corrosive for metal, these solutions are convenient only for good quality stainless steel. The soaking should not exceed 1/2 hour and should be followed by thorough rinsing.**

**3. If instruments are used immediately after soaking, it is not necessary to rinse the chloramine or the polyvidone iodine solution.**

**4. Ethanol and isopropyl alcohol (isopropanol) should be used at 70 % (70°) for the best effectiveness (more concentrated solutions are less effective). The prices, transportation and importation problems limit the use of these alcohols.**

**5. Immersion for several hours in aldehyde solutions, formaldehyde (formalin) and glutaraldehyde (Cidex), provides proper sterilization (destruction of all germs). These solutions however have many disadvantages: thorough rinsing compulsory (toxic residues), toxic vapours (formalin), high cost (glutaraldehyde).**

**Notes:**

- **In order to obtain effective disinfection, equipment must be cleaned before immersion in all these solutions.**
- **Aqueous solutions of cetrimide (Cetavlon), chlorhexidine (Hibitane), Savlon, HAC, Dettol and other common detergent and disinfectant solutions do not provide sufficient disinfection.**

**Soaking instruments in these solutions with the aim of "sterilization" should be avoided. This only provides an illusive feeling of safety and could in fact be a source of contamination.**

### **Sterilizing gases**

- **Ethylene oxide**

**This method cannot be considered in field conditions because of its cost and of the special installation it requires (ethylene oxide is very toxic).**

- **Formol vapour (paraformaldehyde or trioxymethylene or "formol " tablets and Aldhylene)**

**Formol autoclaving also cannot be considered in the field. However formol vapour is often used for "makeshift" sterilization of instruments. The instruments are thoroughly cleaned and dried, then placed in a airtight container for at least 24 hours (minimum temperature of 20°C), either along with formol tablets (5 tablets for 1 litre container), or with formol alcoholic solution (Aldhylene) (1 ml for 1 litre container). Afterwards instruments are rinsed with sterile water. This is often impracticable, but it is absolutely compulsory if there is any visible deposit.**

**Users should be cautious during manipulation as vapors are toxic and highly irritative.**

**This method is not suitable for linen or gauze swabs as they absorb formaldehyde, which is toxic and necroses skin and mucus membranes.**

**This method is not totally reliable and has many disadvantages. It should be abandoned. If it is used an effective disinfection method against HIV (AIDS virus) (eg. boiling) should always be carried out before hand.**

### **Equipment and methods recommended Dispensaries**

#### **Recommended equipment:**

- **1 small autoclave pressure cooker type (volume 15 to 20 litres)**
- **1 powerful kerosene stove (or electric hot-plate)**
- **1 metal mesh basket**
- **Appropriate fenestrated containers (drums)**

#### **Recommended methods:**

- **Instruments, syringes, glass, rubber, plastic, gauze swabs, small drapes: autoclave.**
- **Large drapes, gowns: wash with soap powder, boil if possible, then "sterilize" by ironing.**

## **Mobile teams**

### **Recommended equipment:**

**If possible same equipment as for dispensaries.**

### **Otherwise:**

- **1 container for boiling**
- **Chloramine T or Polyvidone iodine (Betadine)**
- **Formol tablets or Aldhylene (for exceptional use)**

### **Recommended methods:**

**As for dispensaries if possible.**

### **Otherwise:**

- **Metal instruments: boiling (best), otherwise sodium dichloroisocyanurate (NaDCC) or chloramine T or polyvidone iodine (exceptionally, after boiling and drying, instruments may be kept with formol tablet or Aldhylene until utilization)**
- **Needles, syringes: boiling**
- **Swabs: use disposable supplies**

## **Hospitals with surgical facilities**

## **Recommended equipment:**

### **Same equipment as for dispensaries and:**

- **1 large autoclave (interior dimensions about 40 x 60 cm), operating with electricity, gas or kerosene according to local conditions.**
- **2 mesh baskets**
- **Several fenestrated drums (number according to activity)**
- **Several fenestrated instrument boxes**

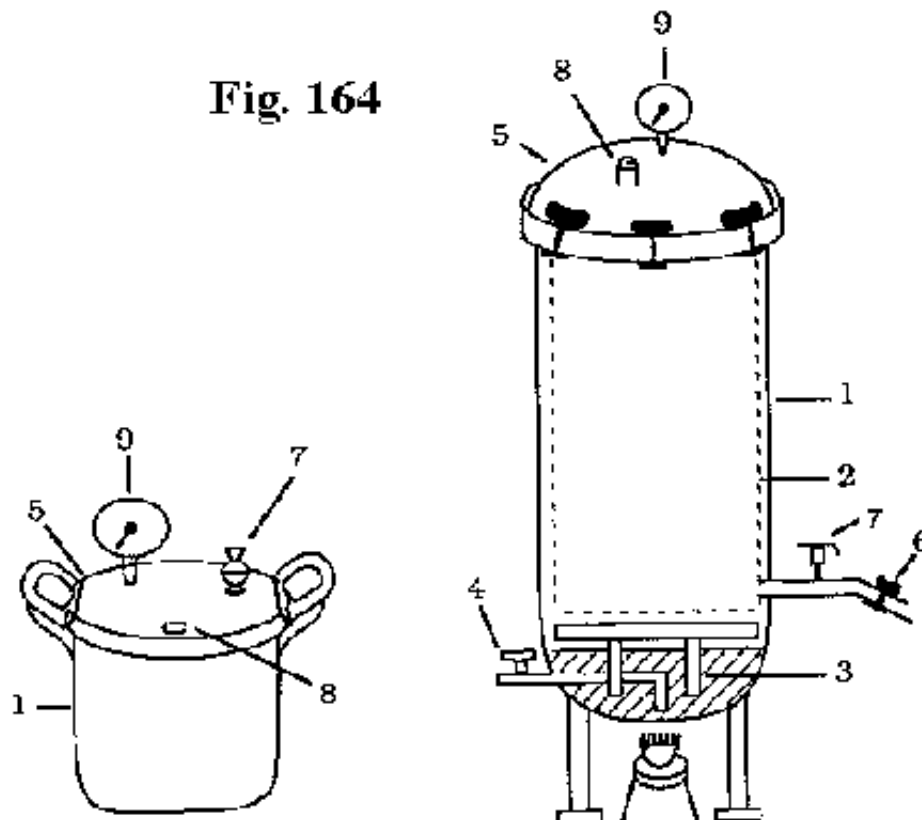
### **If electric current is available continuously for at least 3 hours per day:**

- **1 electric hot air sterilizer**

### **Recommended methods:**

- **Metal instruments, glass: hot air sterilizer if good electric apparatus available, other-wise autoclave**
- **Swabs, linen (gowns, drapes.): large autoclave**
- **Rubber, plastic items, syringes: small or large autoclave (at 121°)**

### **Directions for use of an autolcave**

**Fig. 164**

1. Body of the autoclave
2. Mesh basket to contain packages to be sterilized
3. Metal base to support basket, drums above water
4. Drain tap
5. Lid, usually with a rubber seal and bolt-type catches
6. Tap or valve to allow purging of air during heating phase
7. Pressure valve : regulates the pressure by allowing excess vapour to escape
8. Safety valve
9. Pressure gauge

## FIGURE

### Note:

**In small autoclave, pressure cooker type, there is no purging tape, one uses the valve for purging.**

**The safety valve should not be manipulated during autoclaving (it will function only in case of excessive pressure rise).**

**Pressure gauge shows a pressure scale and sometimes a temperature scale. Pressure could be indicated in different manners.**

**One may consider that 1 bar = 1 kg/cm<sup>2</sup> = 1 atmosphere = 15 psi**

**Temperature could be indicated in °C ou °F (135°C = 275°F; 121°C = 250°F).**

### Operation

**1. Put the require quantity of water in the autoclave before each sterilization (dry heating could damage the autoclave): the level is usually marked or the quantity indicated by the manufacturer. If possible use distilled water or filtered rain water.**

**2. Place the objects to be sterilized in the mesh basket or onto the support, leaving enough room for vapour to circulate freely. The sliding "windows" on drums or containers must be open. Do not overload the autoclave.**

- 3. Close the lid by tightening the bolts in diametrically opposite pairs (as the wheel nuts of a vehicle).**
- 4. With the purging tap or valve open, begin to heat.**
- 5. When a continuous jet of vapour is coming out of this tap/valve, close it.**
- 6. Allow the pressure to rise to 0.5 atm, then open the purge tap/valve for 10 seconds to purge air, then close it.**
- 7. Repeat this purge at about 0.7 atm, then again at about 0.9 atm. After this, all air should have been expelled from the autoclave and only steam will remain.**
- 8. When desired operating pressure (and thus temperature) is obtained, sterilization begins. Start to time it then, not before.**

**The pressure valve regulates the pressure inside the autoclave allowing excess steam escape. There may be two interchangeable valves or positions to operate at either 1 or 2 atm. If a lot of steam is being expelled, heat source should be lowered slightly.**

- 9. After the required duration of sterilization, shut off the heat source.**
- 10. Evacuate water and steam:**
  - For large autoclaves: through drain tap (to be connected outside).**
  - For pressure cooker type autoclaves: evacuate the steam by opening the purge**



**valve. Once pressure drops to zero, open the lid, lift out the basket, pour out the water then replace the basket.**

**11. Allow to cool with the lid slightly open. Residual heat helps dry the sterilized items (the danger of contamination by ambient air is minimal).**

**12. Once items are dry, close the sliding windows on drums.**

**Table 8**

***Pressure or temperature and duration requirements***

Items to be sterilized	Temperature		Pressure <sup>*</sup>		Duration **
	°C	°F	Alm., Bar or kg/cm <sup>2</sup>	PSI	
Instruments, syringes, plastic, glass, rubber	121	250	1	15	30'
Dressing (swabs), linen (gowns, drapes...)	134	275	2	30	20'
	Otherwise 121	250	1	15	40'

\* Over atmospheric pressure  
\*\* Add 5 minutes per 1000 meters above sea level

**TABLE 8**

**Note:**

**If the autoclave is equipped with a drying system, follow the manufacturer's recommendations starting from paragraph 9.**

**(See table 8).**

## **Operation verification**

- **The stove should be powerful! enough to obtain a minimum rise of pressure of 1 atmosphere (1 bar or 1 kg/cm<sup>2</sup> or 15 Psi).**
- **If possible, use sterilization autoclave tests, for example, 3M Autoclave Tape should turn black, brown is insufficient). Warning, do not confuse test tape for hot air sterilizers with that for autoclaves. They are very similar but not interchangeable.**

**Place tests (eg. strip of tape) in the middle of the load into the boxes or drums to ensure that sterilization (temperature, steam, duration) is completed.**

## **Packaging of items for sterilization**

- **Packaging of items: either**
  - **without package if items are to be used immediately**
  - **fenestrated drums or boxes**
  - **heavy duty paper: wrapping paper, kraft paper or news paper (2 layers)**
  - **closely-woven linen (2 layers)**
  - **mixed (1 layer of paper, 1 layer of linen)**

**Paper plus linen is advisable if item is to be stored several weeks (because more resistant than paper alone and best barrier for germs than linen alone).**

**Fenestrated containers should be equipped with a filter (a layer of heavy duty paper see above) accross the windows within the container or around the load to be sterilized so as to filter air during the drying phase after auto-craving. The paper should be checked and renewed regularly.**

- **If the autoclave is not equiped with a drying system, drying up of items inside boxes and drums is often unsastifactory. It is easier when the items are packed with paper or linen.**
- **Packed items should be placed vertically in the autoclave basket (not lying flat).**
- **Small packages and small drums are preferable to large ones.**
- **Needles and syringes: separate plunger and barrel of syringes and stick needles onto a gauze swab.**
- **Swabs and drapes should not be compressed inside boxes or drums.**

